Complete Regression of Vesical Carcinoma Following Urinary Diversion

EDWARD M. MAHONEY, M.D., *Brookline, Massachusetts*

From the Urology Section of the Surgical Service, Veterans Administration Hospital, West Roxbury, Massachusetts.

REGRESSION of urinary vesical carcinoma after urinary diversion has been reported in the literature. In this respect, vesical cancer differs from that group of neoplasms undergoing truly spontaneous regression [1]. Hellstrom [2] mentions, in his study of seventy-four cases of ureterosigmoidostomy, that many papillomatous tumors may markedly subside after bilateral ureteral implantation. Fifteen cases of vesical cancer have been reported which regressed partially or completely within eight days to three months after urinary diversion. Seven of these (five of which had preoperative biopsies) revealed complete histologic regression. (Table I.) Seven regressed incompletely with residual submucosal tumor cells demonstrated in four and benign papillomas in two. One has regressed grossly by cystoscopic examination. (Table II.) The present report adds one case to the four in the literature which, with preoperative and postoperative histology, revealed complete regression after urinary diversion.

CASE REPORT

A sixty-nine year old retired night watchman entered the hospital July 1957 with a chief complaint of having had to void every half hour, day and night, for the past year. During the previous eight months he had resorted to wearing an external collecting device. He denied gross pyuria, hematuria or lithuria. There had been no back pain, fever or weight loss.

Five years earlier, a papillary lesion of the fundus of the bladder, 2 cm. in diameter, had been resected and the base fulgurated. The histologic diagnosis was transitional cell carcinoma, grade III.

TABLE I

COMPLETE REGRESSION OF VESICAL CARCINOMA ON POSTOPERATIVE GROSS AND HISTOLOGIC EXAMINATION

Author	Preoperative Cystoscopic Findings	Results of Preoperative Biopsy
Pearse, 1943 [3]	Infiltrating tumor on posterior wall of bladder	None
Trabucco, 1948 [4]	Papillary carcinoma on right lateral wall and surrounding bladder neck	Papillary carcinoma
Goldberg, 1950 [5]	Patchy, dull, velvety areas with two small sessile papillary growths in right fornix, and another sessile papillary area on anterior wall	Transitional cell carcinoma with marked invasion
Abeshouse and Scherlis, 1951 [6]	Two fungating papillomatous growths on right lateral wall	Papillary carcinoma
Abeshouse and Scherlis, 1951 [6]	Infiltrating tumor of right wall	None
Fort, Harlin and Atkinson, 1951 [7]	Papillomatous growth surrounding neck and protruding into urethra. Larger growths on right inferior lateral margin of vesical neck	Papillary carcinoma, grade II
Mahoney, 1960	Generalized erythema; papillary lesions on left lateral wall	Papillary carcinoma, squamous, grade III

TABLE II

PARTIAL REGRESSION OF VESICAL CARCINOMA ON POSTOPERATIVE GROSS AND HISTOLOGIC EXAMINATION

Author	Preoperative Cystoscopic Findings	Results of Preoperative Biopsy	Pathology Report on Excised Bladder
Pearse, 1943 [3]	Sessile tumor, 3 cm. in diameter, projecting 2 cm. into bladder cavity, posterolateral to left ureteral orifice	None	Gross: no neoplasm; histology: solid plugs of carcinoma in muscle layer
Davis, 1948 [8]	Crater-like 2 cm. ulceration with elevated edge situated behind trigone and to left of midline	Carcinoma	Gross: no neoplasm; histology: cancer cells underlying normal mucosa
Davis, 1948 [8]	Slightly elevated, 2½ cm. lesion with edematous and reddened surface on left lateral wall	Carcinoma	Gross: no neoplasm; histology: cancer cells underlying normal mucosa
Abeshouse and Scherlis, 1951 [6]	Recurrent large papillary tumor with infiltration at base on right lateral wall	Transitional cell carcinoma, grade II	Gross: two small papillomas near right ureteral orifice; histology: no cancer cells
de Gironcoli 1951, [9]	Large cauliflower-like growth filling entire right half of bladder	Papanicolaou smear positive	Normal bladder with slight reddening by cystoscopic examination
de Gironcoli 1951, [9]	Growth involving entire neck of bladder	Papillary carcinoma	Gross: small papillary lesion on neck of bladder; histology: simple papilloma
Crone-Munzebrock and Boeminghaus, 1953 [10]	Broad-based solid tumor on posterior wall, palpable bimanually	Solid carcinoma	Gross: no neoplasm; histology: tumor cells
Brosig, 1953 [11]	Large tumor obscuring left ureteral orifice	Solid carcinoma	Gross: no neoplasm; histology: solid infiltrating carcinoma involving upper layers of muscular wall

(Fig. 1.) Subsequently, he had done well and was essentially asymptomatic until one year prior to this admission.

His family history was negative for carcinoma, and system review disclosed no abnormalities. No history of exposure to vesical carcinogens was elicited.

On physical examination, the blood pressure was 120/75 mm. Hg; there was no costovertebral tenderness or renal enlargement. The prostate was benign and estimated to weigh 30 gm.

Laboratory studies revealed that the urine was completely negative for abnormalities except for a rare leukocyte in a spun sediment; the blood urea nitrogen was 15 mg. per cent. The urine culture revealed Micrococcus tetragenus. The leukocyte count of the blood was 8,200 per cu. mm. and the hematocrit was 43 per cent. X-ray films of the chest and skeleton revealed no evidence of metastases. Barium enema and sigmoidoscopy showed no invasion of the large bowel.

The bladder capacity was found to be 40 cc. A cystogram demonstrated bilateral ureteral reflux and an irregularity of the superior and right areas of the bladder. The excretory urogram revealed no abnormality of the upper urinary tract. The mucosa of the bladder at cystoscopy appeared to be intensely erythemic throughout with a diffuse area of minute papillary lesions on the left lateral wall. Biopsy specimens from the right and left lateral walls, and a fragment of tissue floating free within the lumen of the bladder contained malignant cells. The histologic diagnosis was papillary carcinoma, squamous, grade III. (Fig. 2.)

First-stage bilateral ureterosigmoidostomy, using a tunnel and elliptic mucosa-to-mucosa anastomosis, was performed. Seven weeks later, after a stormy postoperative course, the patient underwent abdominoperineal total cystectomy. Pathologic examination of the bladder, despite an intense search involving the microscopic study of multiple sections of the bladder, failed to reveal any malignant cells either in the wall or mucosa of the specimen.

The patient's postoperative course has been smooth except for periods during which he elected

FIG. 1. Section from biopsy of tumor of bladder showing anaplastic character of epithelium.

FIG. 2. Section from biopsy of tumor of bladder. Observe disorganized growth pattern and variation in size, shape and staining characteristics of nuclei.

to omit the sodium bicarbonate medication and hyperchloremic acidosis developed. He is asymptomatic and feeling well. His blood urea nitrogen was 17.5 mg. per cent fifteen months following surgery, and there was no evidence of recurrent tumor.

The patient died of confluent bronchopneumonia of the right middle, right lower and left lower lobes, and focal myocarditis, as demonstrated at autopsy, two and a half years after his first admission. Transitional cell carcinoma was found in the liver, retroperitoneum and perirectal area, the latter causing obstruction of the left ureter. This does not alter the basic thesis, but rather indicates that metastatic spread had occurred prior to urinary diversion and the subsequent complete regression of his primary carcinoma.

COMMENTS

A sixteenth case of regression of vesical carcinoma following urinary diversion, and the fifth with pre- and postoperative histology to demonstrate complete regression, is added to the literature. The short interval, varying from eight days to three months after diversion, during which the carcinomas regressed is of interest and supports the view that these neoplasms were dependent for their survival upon a continued supply of urine-borne carcinogens. The occurrence in normal urine of carcinogenic tryptophan metabolites, and their increase in patients with vesical neoplasia, led to Wallace's [13] concept that the effect of the carcinogen was dependent upon the duration of exposure and its urinary concentration. This possibility is supported by the two clinical observations [9,11] in which tumor partially regressed following unilateral ureterosigmoidostomy with diversion from the bladder of presumably one-half of the total urinary volume. Scott's [12] experimental studies revealed similar findings. His intact dogs which were fed beta-naphthylamine all demonstrated neoplasia of the bladder, while those animals whose bladders were deprived of urine from one kidney by unilateral ureterosigmoidostomy failed to develop vesical tumors.

The described clinical instances of tumor regression subsequent to diversion are consistent with the investigations implicating urine-borne carcinogens. At this time, Wallace's [13] suggestion that elimination of stasis and the production of a dilute urine may have a preventive influence on vesical neoplasia deserves serious consideration.

SUMMARY

A sixteenth case of complete regression of vesical tumor following urinary diversion is presented. The reviewed cases present clinical evidence to support and encourage studies implicating urine-borne carcinogens in vesical neoplasia.

REFERENCES

1. Dunphy, J. E. Some observations on the natural behavior of cancer in man. *New England J. Med.*, 242: 167, 1950.
2. Hellstrom, J. Some views on treatment of vesical tumors, especially ureteral implantation in [illegible] total cystectomy. *Urol. & Cutan. Rev.*, 52: 385, 1948.
3. Pearse, R. Discussion of Davis, E. [14].
4. Trabucco, A. Discussion of Davis, E. [8].
5. Goldberg, L. G. Complete regression of carcinoma of the bladder following ureterosigmoidostomy. *J. Urol.*, 63: 116, 1950.
6. Abeshouse, B. S. and Scherlis, I. Spontaneous disappearance or retrogression of bladder neoplasm; review of literature and report of three cases. *Urol. & Cutan. Rev.*, 55: 65, 1951.
7. Fort, C. A., Harlin, H. C. and Atkinson, H. D. Regression of cancer of the urinary bladder following uretero-intestinal anastomosis. *J. Urol.*, 66: 688, 1951.
8. Davis, E. Disappearance of carcinomatous ulceration of bladder following ureterosigmoidostomy; report of two cases. *J. A. M. A.*, 137: 450, 1948.
9. de Gironcoli, F. Über das Verschwinden von Blasentumoren nach Harnableitung. *Verhandl. deutsch. Gesellsch. f. Urol.*, p. 308, 1951.
10. Crone-Münzebrock, H. and Boeminghaus, H. Ruckbildung von Blasentumoren nach Harnableitung. *Ztschr. f. Urol.*, 46: 386, 1953.
11. Brosig, W. Der Einfluss der Urinausschaltung auf das Wachstum von Blasentumoren. *Beitr. z. klin. Chir.*, 194: 278, 1957.
12. Scott, W. W. and Boyd, H. L. Study of the carcinogenic effect of betanaphthylamine on normal and substituted isolated sigmoid loop bladder of dogs. *J. Urol.*, 70: 914, 1953.
13. Wallace, D. Aetiological factors in bladder tumors. *Post-Grad. M. J.*, 33: 494, 1957.
14. Davis, E. Chemical carcinogenesis, drugs, dyes, remedies and cosmetics, with particular reference to bladder tumors. *J. Urol.*, 49: 14, 1943.
15. Richardson, M. H. A case of apparently hopeless infiltration of left axilla and scapula by round-celled sarcoma. *Tr. Am. S. A.*, 16: 309, 1898.

Reprinted from the July issue of The American Journal of Surgery volume 100, number 1, pages 133-136, copyright 1960 and printed in the U.S.A. Published by *The American Journal of Surgery, Inc.*, 11 East 36th Street, New York

This will introduce

Leo Szilard

WHO IS A MEMBER IN GOOD STANDING OF

The Quadrangle Club

UNIVERSITY OF CHICAGO

OCT - - 1957

EXPIRES

Margaret E. Perry

SECRETARY

BLUE CROSS

Plan for Hospital Care

OPERATED NOT-FOR-PROFIT BY THE
HOSPITAL SERVICE CORPORATION
CHICAGO

COMPREHENSIVE CERTIFICATE

SZILARD L

AND FAMILY MEMBERS, IF ENROLLED, ARE ENTITLED TO BENEFITS UNDER

90298- 4828

CERTIFICATE NUMBER

11- 1- 44

EFFECTIVE DATE OF CERTIFICATE

THIS IS YOUR PERMANENT IDENTIFICATION CARD, TO BE USED AT THE HOSPITAL

John R. Manning

Executive Director

VOTER'S IDENTIFICATION CARD

ISSUED BY

BOARD OF ELECTION COMMISSIONERS

ROOM 308, CITY HALL, CHICAGO 2, ILLINOIS

10/44

Leo Szilard

1155 E. 57th St.

CHICAGO , ILL. P43 W5

WHOSE NAME APPEARS ABOVE, IS REGISTERED AS A VOTER.

IF EITHER NAME OR ADDRESS IS INCORRECT, NOTIFY BOARD.

EDMUND K. JARECKI
COUNTY JUDGE

JOHN S. RUSCH, CHIEF CLERK

HARRY A. LIPSKY
MABEL G. REINECKE
WILLIAM B. DALY
} COMMISSIONERS

SEE OPPOSITE SIDE FOR TRANSFER.

224

FORM 261

TRANSFER OF REGISTRATION

IF YOU SHOULD MOVE, WRITE IN THE NEW ADDRESS, SIGN YOUR NAME AND MAIL TO BOARD OF ELECTION COMMISSIONERS, ROOM 308, CITY HALL, CHICAGO 2, ILL. IF YOU CHANGED YOUR NAME BY MARRIAGE OR OTHERWISE, YOU MUST RE-REGISTER IN PERSON.

DATE MOVED_____ 194___

NEW ADDRESS_____

_____

CITY, TOWN, ETC. P. O. ZONE NO.

SIGNATURE_____

Change of Address Cannot Be Accepted In the 28-Day Period Preceding Any Electio

DAY AND NIGHT PHONE
TABOR 5-1611

PRACTICE LIMITED TO
UROLOGY

I. GERSH, M.D.

HOURS - BY APPOINTMENT

242 METROPOLITAN BLDG.
DENVER 2, COLORADO

THE ROYAL MARSDEN HOSPITAL SURREY BRANCH
Downs Road, Sutton, Surrey. Telephone: VIGilant 6011

30 Oct 67

Dear Trudi,

Here is the report of the blood count you had performed the day you came out to Sutton. I hope you have had a chance to have someone in Washington or at the N.I.H. look you over. I'd be most interested to hear what they think of your rising lymphocyte count.

I trust you and Leo had a pleasant trip back to the states. I am quite sure you are back in your usual activities, but I hope you will find a moment to keep in touch from time to time.

With all good wishes,

Sincerely,

Sam

THE JOURNAL OF UROLOGY
Vol. 87, No. 3 March 1962

TECHNICAL ADVANCES IN THE PREVENTION OF URINARY TRACT INFECTION

ROBERT E. DESAUTELS, CARL W. WALTER, ROGER C. GRAVES AND J. HARTWELL HARRISON

From the Peter Bent Brigham Hospital, the New England Deaconess Hospital, and the Department of Surgery, Harvard Medical School, Boston, Mass.

It has been demonstrated previously that aseptic management of the catheter and the urinary catheter drainage system achieves a significant reduction in the usually expected incidence of urinary infection. The present paper describes further experience with this study and offers some simplifications and improvements for the management of catheter drainage.

METHODS

It is necessary to re-emphasize that asepsis is mandatory, regardless of the equipment used. Introduction of bacteria at the time of catheterization or cystoscopy is avoidable if proper technique is employed (fig. 1).

The area of the urethral meatus is washed with a surgical detergent containing hexachlorophene and then with 1:1000 or 1:750 benzalkonium chloride.* The distal urethra is irrigated with aqueous benzalkonium chloride, 1:1000, using an Asepto syringe, before the catheter or instrument, well lubricated with a sterile water-soluble jelly, is passed.

Daily cleansing about the urethral meatus with aqueous benzalkonium chloride (once a day in males, twice a day in female patients) followed by the application of a wet benzalkonium chloride dressing about the glans penis and adjacent catheter in male patients, or a catheter impregnated with tetramethylthiuramdisulphide, was used as a means of preventing the entry of bacteria around the catheter either at the urethral meatus or the cystostomy sinus or the nephrostomy sinus.

Once attached to the drainage set, the catheter is not detached unless absolutely required, and then only with careful disinfection of the junction by an excess of 70 per cent ethyl alcohol. No irrigations are carried out routinely, even in the postoperative cases and in the latter they are done only where specifically necessary. Two different sterile drainage sets were tested: one, a standard rubber tubing with glass connector proximal and adapter attached to a two-hole rubber stopper distally for use in a sterile one-liter bottle; the other, a sterile plastic tubing with a plastic drip chamber at its distal end as an air break to be used with sterile plastic bags and supporting frame* (fig. 2).

Urine was taken for culture and colony count at the start when indicated during drainage, and at end of period. Most cultures were either sterile or definitely positive, i.e. over 100,000 organisms per milliliter. A few had Staphylococcus albus or aureus in counts less than 1000 per milliliter and were considered of no clinical significance. Subsequent cultures proved this assumption correct.

RESULTS

Benzalkonium dressing. In 82 patients, benzalkonium cleansing about the catheter and a benzalkonium dressing were used (table 1). Forty-four patients had a suprapubic tube, and three of these had a positive terminal culture. Thirty-eight patients had a urethral catheter, and 11 of these had a positive terminal culture. In 18 of these patients, no antibiotic or sulfonamide was given, and a positive culture was obtained in two. Three patients with initial positive cultures had a sterile culture at the time the catheter was removed, following treatment with an antibiotic.

Impregnated catheter. In 73 patients, a catheter impregnated with tetramethylthiuramdisulphide was used, and nine of these had positive cultures when the catheter was removed (table 2). Fifty-five patients of this group had urethral catheter drainage; nine had positive terminal cultures. Of 13 on suprapubic drainage, one had a positive culture, and of five on nephrostomy drainage,

Read at annual meeting of American Association of Genito-Urinary Surgeons, Las Vegas, Nevada, May 17-19, 1961.

* Zephiran chloride; Winthrop-Stearns, Inc.

* Fenwal Bedside Drainage Set Y1980, Fenwal Labs, Inc.; Bardic Bags and Frame, C. R. Bard, Inc.

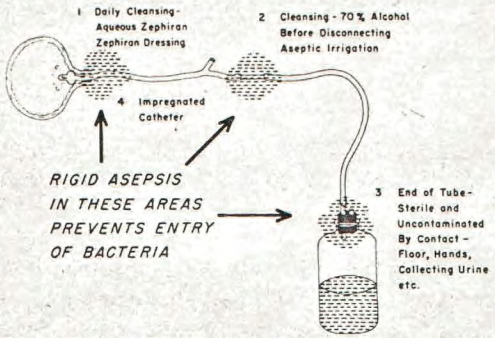

FIG. 1



FIG. 2. Plastic drainage set with drip chamber. Large outflow tube prevents filling of chamber, thereby providing constant air break.

none had a positive culture when the catheter was removed. In this group, no medication was given in 30, and positive cultures were obtained in six of these 30 while on drainage. Two of the six were sterilized before the catheter was removed. Of 11 patients with initially positive cultures, eight had a sterile culture, after treatment with an antibiotic, at the time the catheter was removed.

Bottle drainage system. The bottle system was employed in 115 patients, and of these, 18 had positive terminal cultures (table 3). Eight of these positive cultures were believed definitely related to contamination of the end of the drainage system. Four of the 18 appeared related to inadequate care of the dressing, and three of the 18 appeared related to contamination at the connection of catheter and drainage set.

TABLE 1. *Catheter with benzalkonium dressing*

Terminal Cultures	Urethral	Suprapubic
Negative	31	41
Positive	11	3
Total	38	44

TABLE 2. *Impregnated catheter*

Terminal Culture	Urethral	Suprapubic	Nephrostomy
Negative	46	12	5
Positive	9	1	0
Total	55	13	5

TABLE 3. *Positive terminal urine cultures*

Apparent Cause	No.	Type of Apparatus
Contamination at surgery (long transurethral resection)	1	Impregnated catheter with plastic drainage set
Infected at start and throughout	3	Impregnated catheter with plastic drainage set
Contamination at urethral meatus (inadequate care of dressing)	3	Regular catheter with bottle system
Contamination at cystostomy sinus (inadequate care of dressing)	1	Impregnated catheter with bottle system
Contamination at connecting tube (tube disconnected without aseptic precautions)	3	Regular catheter with bottle system
	2	Impregnated catheter with bottle system
Contamination at end of drainage set (bottle overflowed, etc.)	8	Regular catheter with bottle system
Unknown	3	Regular catheter with bottle system
Total	24	

Plastic set with drip chamber. The new plastic drainage set with a drip chamber was used in 40 patients, and of these, six had a positive terminal culture (table 3). Two were related to contamination at the junction of catheter and connecting tube, one to probable initial contamination at time of surgery, and the other three were infected initially, keeping the same organism throughout.

The duration of drainage was at least 7 days in the average case with a variation of from 2 days to 6 months. Positive cultures occurred with no definite relation to the length of time involved.

DISCUSSION

It is significant that in cases under careful observation while on catheter drainage, a positive urine culture can almost always be related to a break in technique or a defect in the system. In most systems now in use, the end of the drainage set is a common port of entry for bacteria. Therefore, the use of an apparatus that prevents retrograde contamination is essential. Where routine irrigations of the catheter are carried out, contamination almost always occurs. Only with thorough disinfection of the junction of catheter and connecting tube and use of extreme care, can irrigations be done safely. This is usually lacking in the average hospital situation. Furthermore, irrigation is not needed when the urine is clear and sterile but only when a large amount of clot or debris is present. The use of bacteriostatic compound, either about the catheter or in the catheter substance, has resulted in a significant reduction in the incidence of positive cultures. The use of an impregnated catheter is simpler and probably more foolproof than the dressing. However, in the case of the short female urethra and short cystostomy sinus, it is still important to maintain good hygiene about the tube, because a sudden motion can conceivably carry an innoculum of bacteria-laden material from the external environment all the way into the bladder without inactivation by the catheter surface. Irrigating the distal urethra with aqueous benzalkonium chloride, which we have found to be perfectly safe, has eliminated the few bacteria (with a resulting low colony count) that were so commonly found in cultures taken at catheterization and cystoscopy before this maneuver was carried out. This is felt to be especially important in catheterizing female patients, because it is difficult to cleanse the meatus adequately by simple external washing. The use of a bacteriostatic lubricant may also be of value.

Prophylactic anti-bacterial treatment is not essential. However, where a single contaminating episode has taken place it is of value. When a steady stream of bacteria is entering the urinary tract, prophylactic treatment selectively preserves the resistant competitors. As indicated by the aforementioned statistics, an attempt to

sterilize an infected urinary tract is definitely worthwhile in the patient on catheter drainage, provided that new bacteria are prevented from entering the system.

To date, the simplest and most effective system for catheter drainage appears to be the catheter impregnated with tetramethylthiuramdisulphide and the plastic drainage set with drip chamber for use with a plastic bag.

SUMMARY AND CONCLUSIONS

It is emphasized that aseptic technique is essential in the use of the catheter and catheter drainage system. Maintenance of a closed system with a bacteriostatic catheter to prevent entry of bacteria about the meatus, and an air break at the end of the drainage tube to prevent retrograde invasion of bacteria, protects the urinary tract from infection.

MEMBERSHIP CARD

Plan for Hospital Care

HOSPITAL SERVICE CORPORATION
MERCHANDISE MART • CHICAGO • WHITEHALL 5300

SZILARD, L

29.8 – 4828 11 – 1 – 44

CERTIFICATE NUMBER

EFFECTIVE DATE OF SUBSCRIBER'S CERTIFICATE

THIS IS YOUR PERMANENT IDENTIFICATION CARD, TO BE USED AT THE HOSPITAL

Robert T Sherman

PRESIDENT

S120

PLAN HOSPITALS

IN CHICAGO

ALEXIAN
AMERICAN
AUGUSTANA
BELMONT COMMUNITY
BETHANY
BETHANY METHODIST
CHICAGO LYING-IN
CHICAGO MEMORIAL
CHILDREN'S MEMORIAL
COLUMBUS
COOK COUNTY
ENGLEWOOD
EVANGELICAL
GARFIELD PARK
GRANT
HENROTIN
HOLY CROSS
HOME FOR DESTITUTE CRIPPLED CHILDREN
HOSPITAL OF ST. ANTHONY DE PADUA
ILLINOIS CENTRAL
ILLINOIS MASONIC
JACKSON PARK
LEWIS MEMORIAL MATERNITY
LORETTO
LUTHERAN DEACONESS
MARTHA WASHINGTON
MERCY
MICHAEL REESE
MOTHER CABRINI
MT. SINAI
NORWEGIAN-AMERICAN
PASSAVANT MEMORIAL
PRESBYTERIAN
PROVIDENT
RAVENSWOOD
ROSELAND COMMUNITY
ST. ANNE'S
ST. BERNARD'S
ST. ELIZABETH'S
ST. GEORGE'S
ST. JOSEPH
ST. LUKE'S
ST. MARY OF NAZARETH
SOUTH CHICAGO
SOUTH SHORE
SWEDISH COVENANT
UNIVERSITY
UNIVERSITY OF CHICAGO CLINICS (ALBERT MERRITT BILLINGS-BOBS ROBERTS MEMORIAL)
WALTHER MEMORIAL
WESLEY MEMORIAL
WOMEN AND CHILDREN'S
WOODLAWN

OTHER CITIES

COMMUNITY (EVANSTON)
COMMUNITY (GENEVA)
COPLEY (AURORA)
DELNOR (ST. CHARLES)
ELMHURST
EVANSTON
HIGHLAND PARK
HINSDALE
INGALLS MEMORIAL (HARVEY)
LAKE FOREST
LITTLE COMPANY OF MARY (EVERGREEN PARK)
MACNEAL MEMORIAL (BERWYN)
OAK PARK
ST. CATHERINE'S (E. CHICAGO, IND.)
ST. CHARLES (AURORA)
ST. FRANCIS (BLUE ISLAND)
ST. FRANCIS (EVANSTON)
ST. JAMES (CHICAGO HEIGHTS)
ST. JOSEPH-MERCY (AURORA)
ST. JOSEPH'S (ELGIN)
ST. JOSEPH'S (JOLIET)
ST. MARGARET (HAMMOND, IND.)
ST. MARY'S (DEKALB)
ST. MARY (KANKAKEE)
ST. MARY'S MERCY (GARY, IND.)
ST. THERESE'S (WAUKEGAN)
SHERMAN (ELGIN)
SILVER CROSS (JOLIET)
VICTORY MEMORIAL (WAUKEGAN)
WESTLAKE (MELROSE PARK)
WEST SUBURBAN (OAK PARK)

Present This Card Upon Admission To Hospital

THE UNIVERSITY OF CHICAGO

IDENTIFICATION CARD

ISSUED BY THE OFFICE OF THE COMPTROLLER

Leo Szilard

Professor

Institute Radiobiology & Biophysic

EXPIRATION DATE: Indef. Tenure

Leo Szilard

SIGNATURE

Szilard, Leo (C63-10769) Dr. Whitmore 5/10/63

5/5/63: Catheterized urine specimen

No cytologic evidence of a malignant neoplasm is found.

Red blood cells and pmn's are numerous.

Class I

J.F. Seyb

Papanicolaou Cytology Laboratory

MEMORIAL CENTER

ELECTROCARDIOGRAPH REPORT

Name SZILARD, LEO DR. 21-02-93 Room No. 812

Address

Date Taken June 3, 1960 EKG No. 30307 Position: Recumbent ☐ Semi-Recumbent ☐

Rhythm Normal sinus rhythm

Electrical Axis Left axis deviation Auricular rate 85 Ventricular rate 85

P-R (A-V) O. 18 sec. (QRS (I—V) O. 08 sec. Q-T O. 36 sec.

Interpretation and Conclusions:

Low T in I, AVL and V5-6

T wave abnormalities indicate myocardial disease

and/or extracardiac effect, since 4/1/60.

Date Reported June 6, 1960 By Irwin Nydick M.D.

IRWIN NYDICK, M.D.

10710

MEMORIAL CENTER

Name [illegible] Date taken 6-3-60 Room No. 812

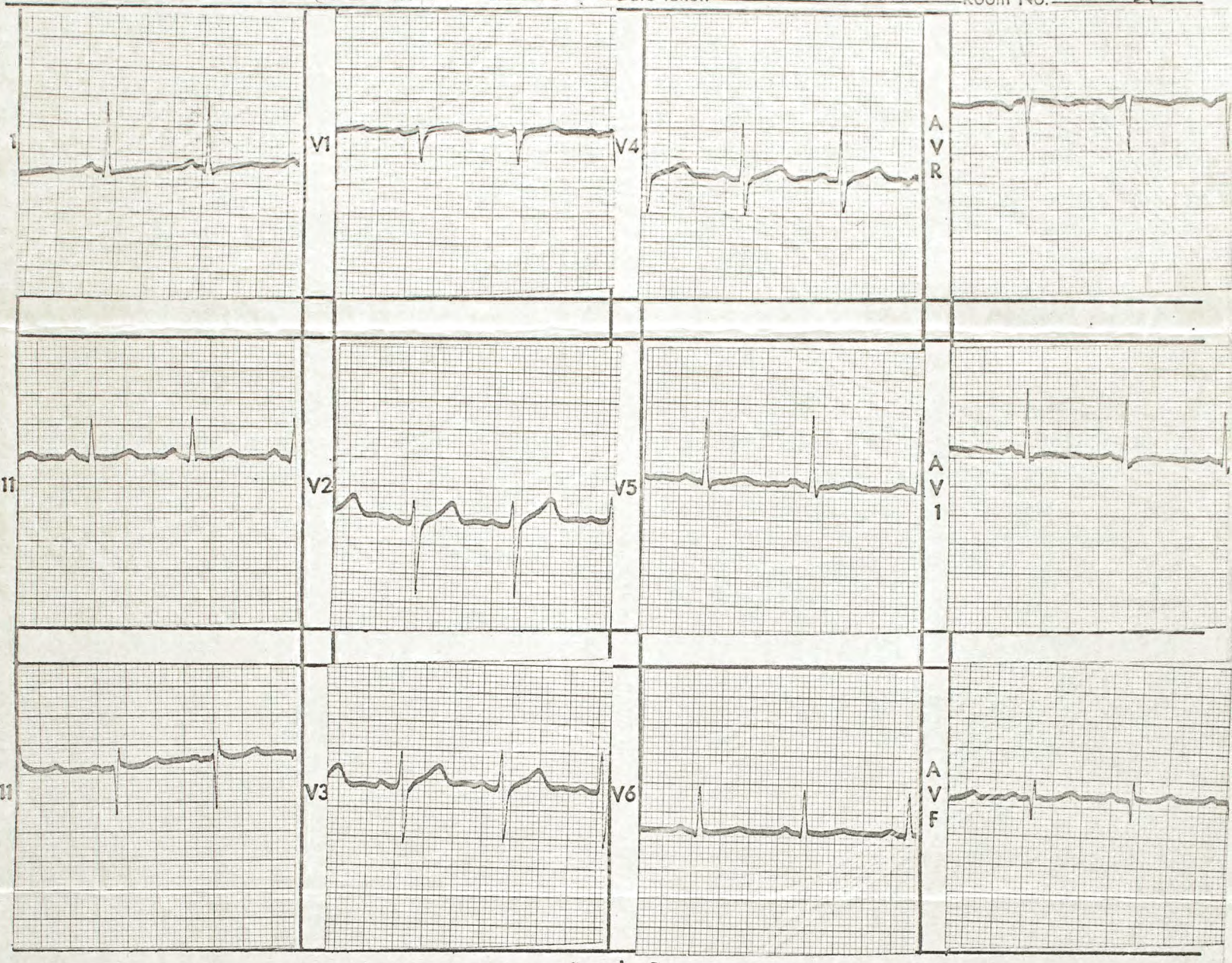

Lead 2

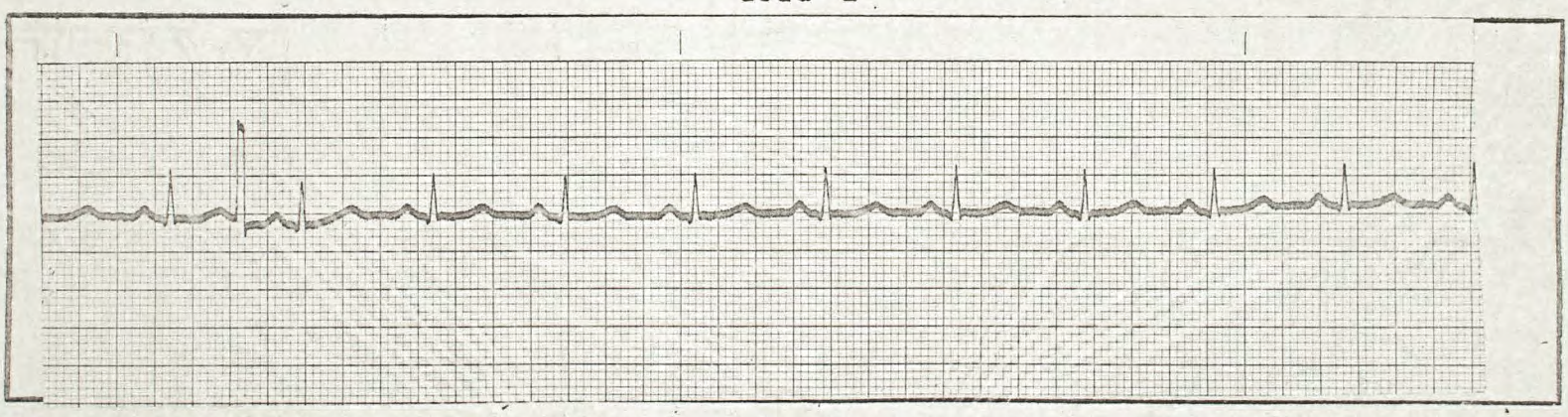

10705


V6

Dr. Stilert
7-15-58

Permapaper

Dr Szilard

3-18-58

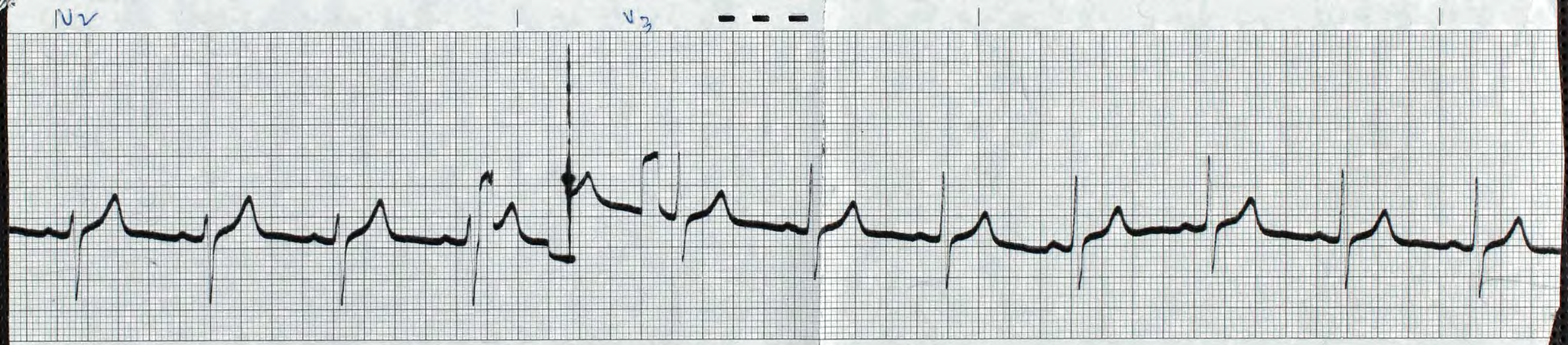

Dr Spilerd

3-18-58

Szilard, Dr. Leo (C63-20890) Dr. Whitmore 9/16/63

9/11/63: Catheterized urine specimen

No cytologic evidence of a malignant neoplasm is found.

PMN's are fairly numerous.

Class I

W.D. Johnson
Papanicolaou Cytology Laboratory

ÉLECTROCARDIOGRAMME

Mr. le Prof. Szilard

Date 2 SEP. 1959

Dr J.-P. DORET
1, rue Emile-Yung
Genève

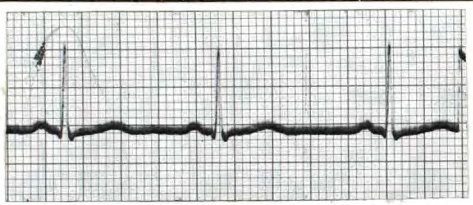

DI

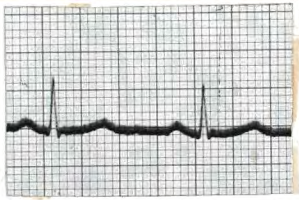

DII

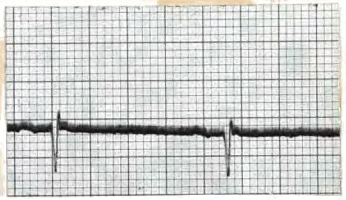

DIII

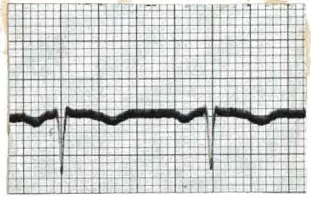

AVR

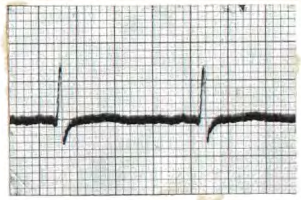

AVL

AVF

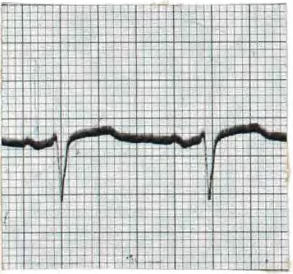

V1

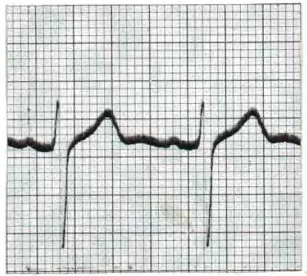

V2

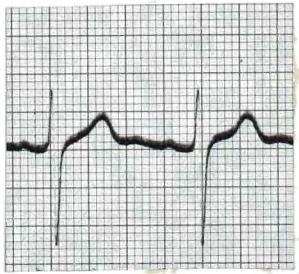

V3

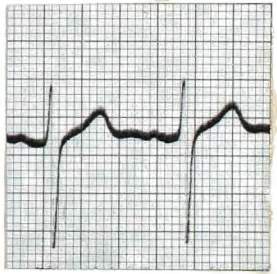

V4

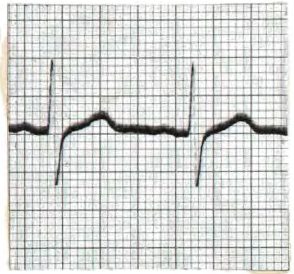

V5

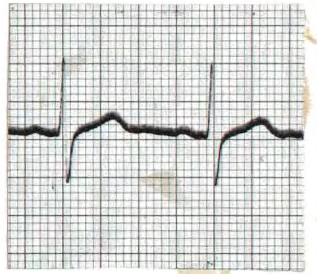

V6

Szilard, Dr. Leo (C60-21499) Dr. Whitmore 11/22/60

Voided urine specimen of 11/21/60

One cells is found showing atypical features which may be due to the effects of radiation. Polymorphonuclear leucocytes are numerous.

Class II

J.F. Seybolt
Papanicolaou Cytology Laboratory

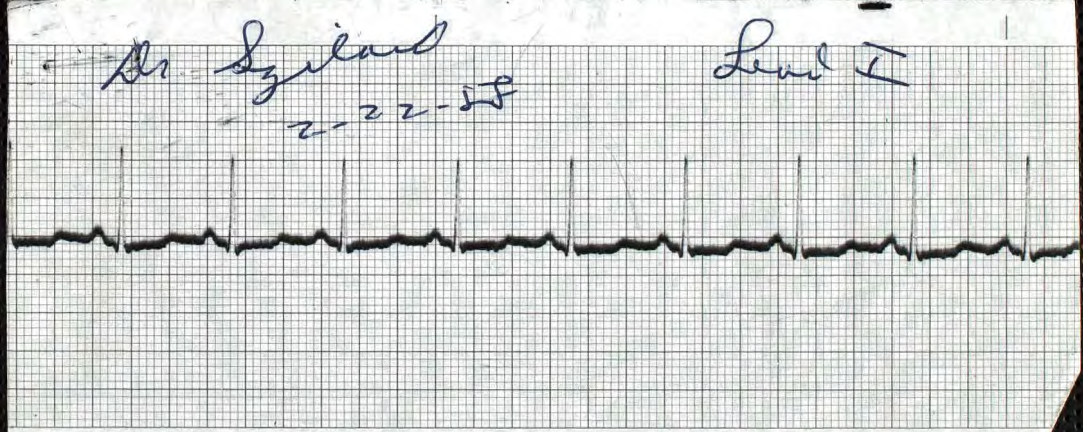
Dr Szilard
2-22-58
Lead I
SANBORN VISO-CARDIETTE Permapaper

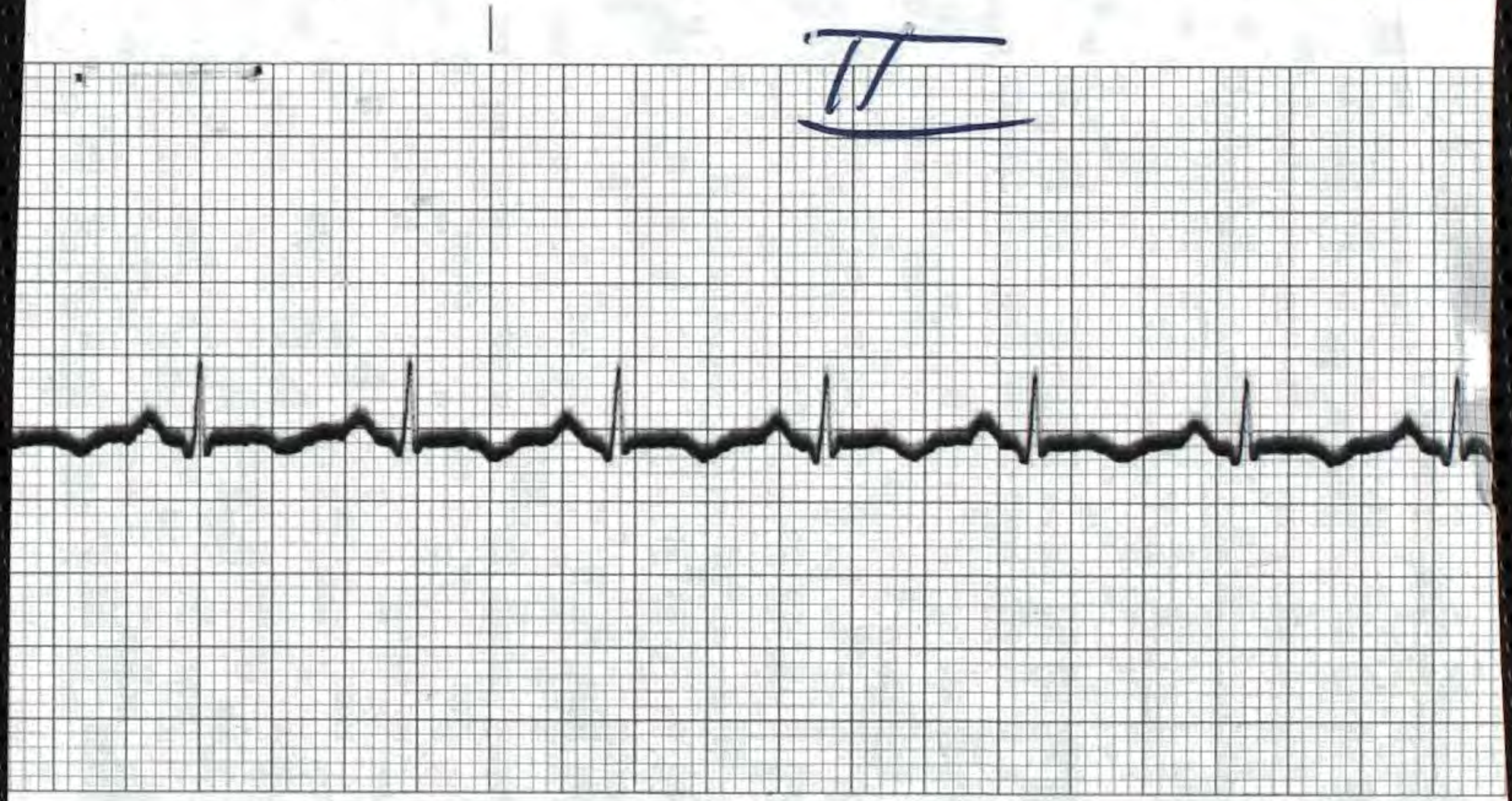
II


III

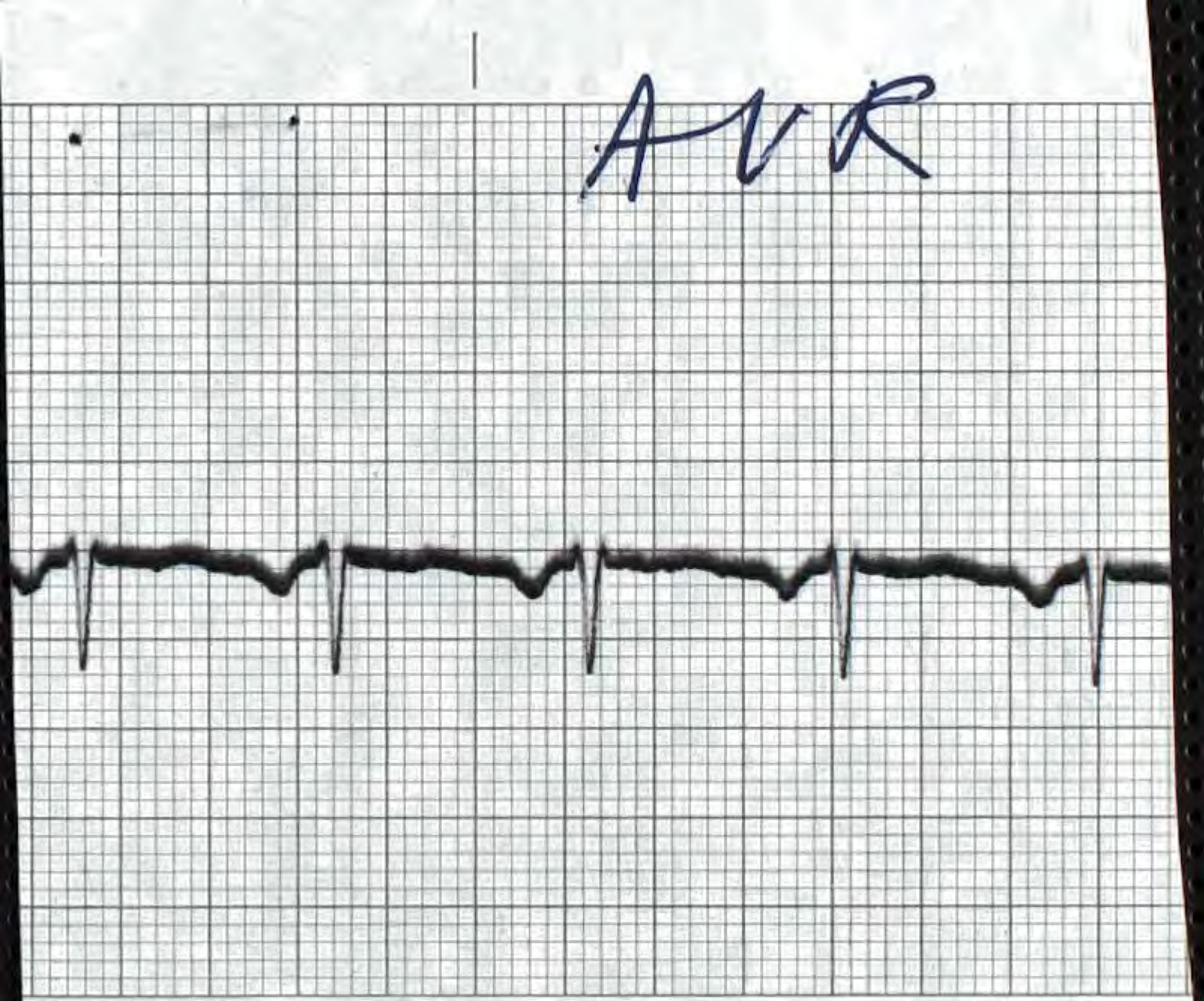
AVR
SANBORN VISO-CARDIE

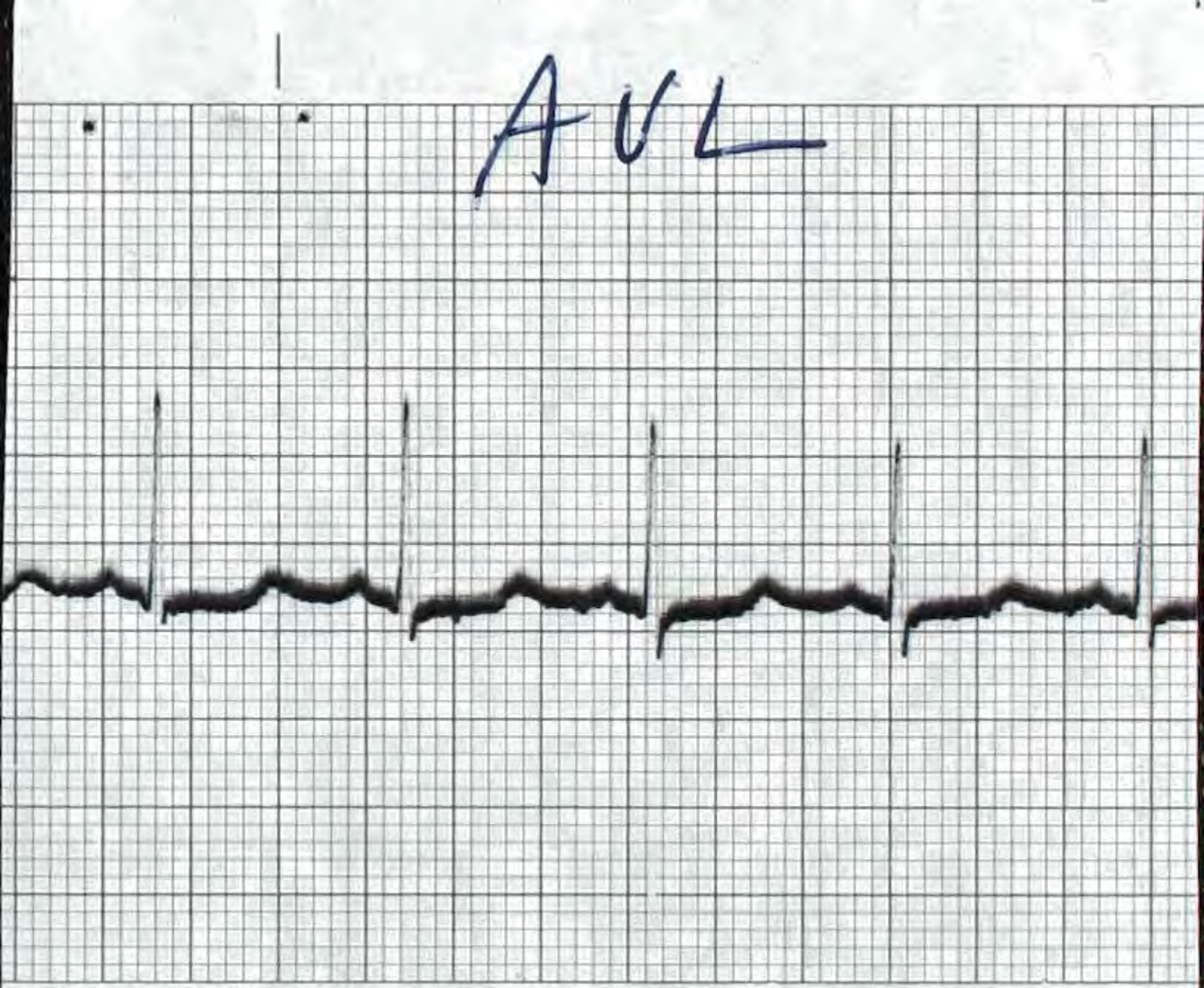

er

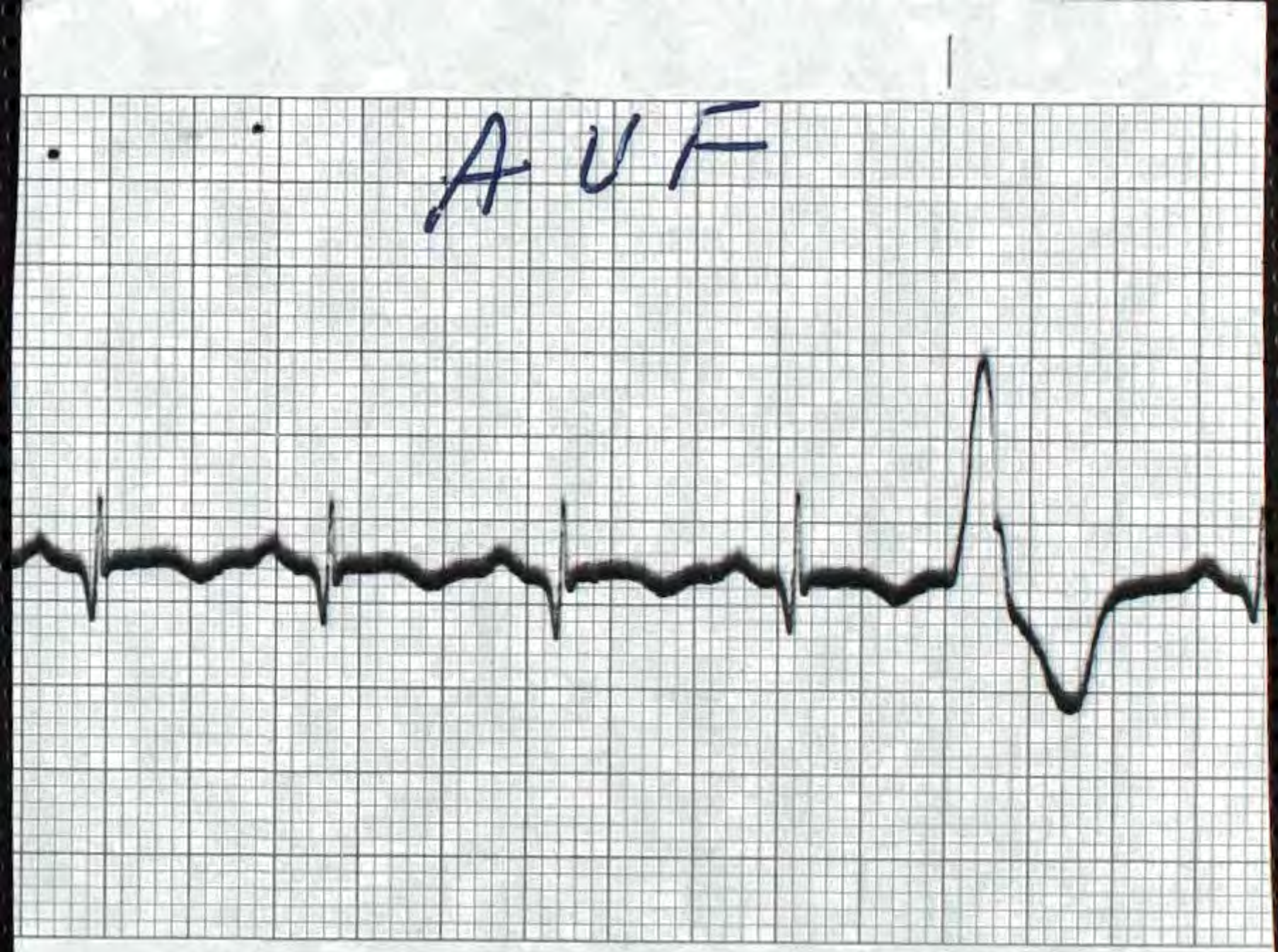

SANB


V3R

SANBORN VISO-CARDIETTE *Permapaper*

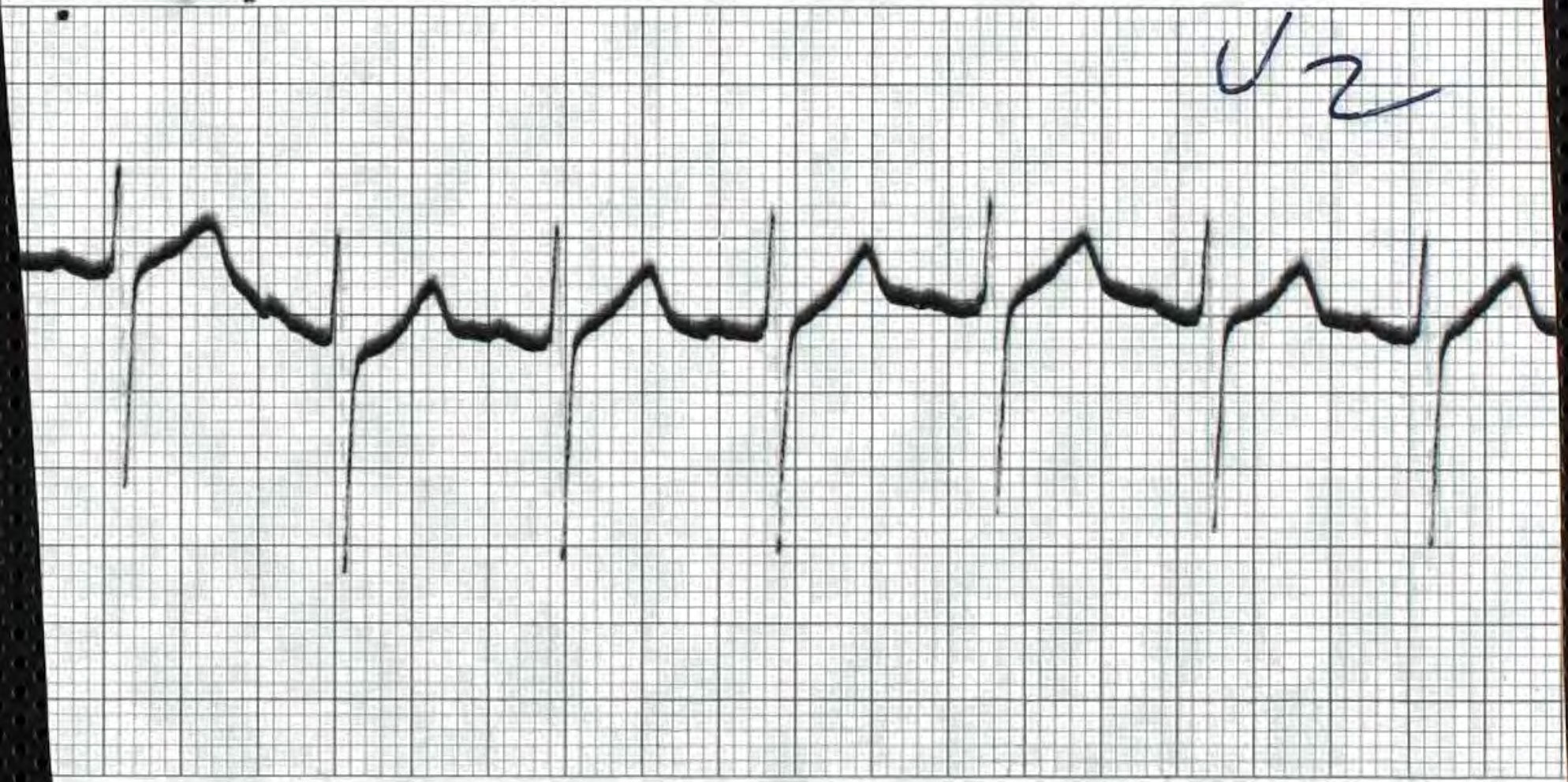
V2

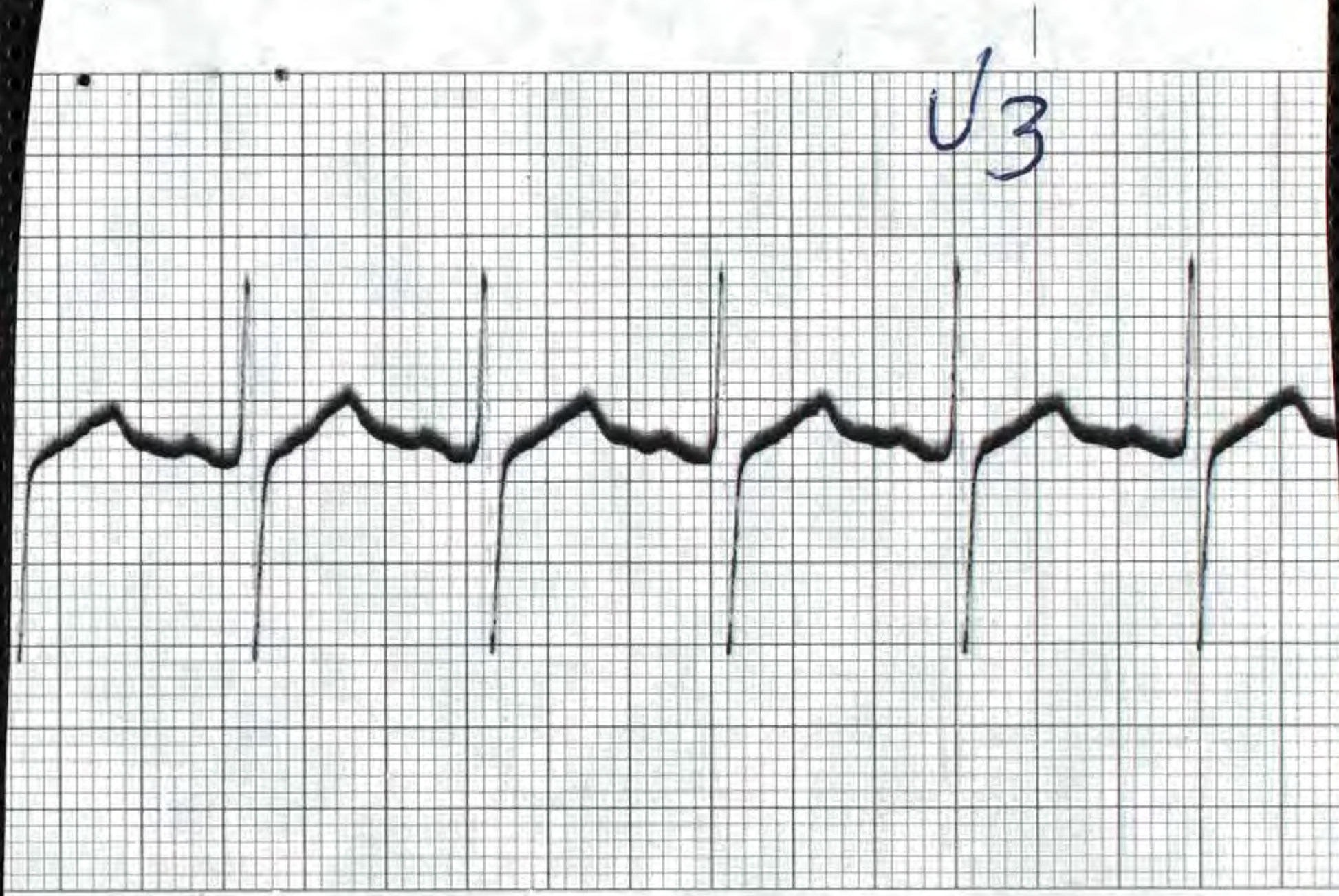
U3

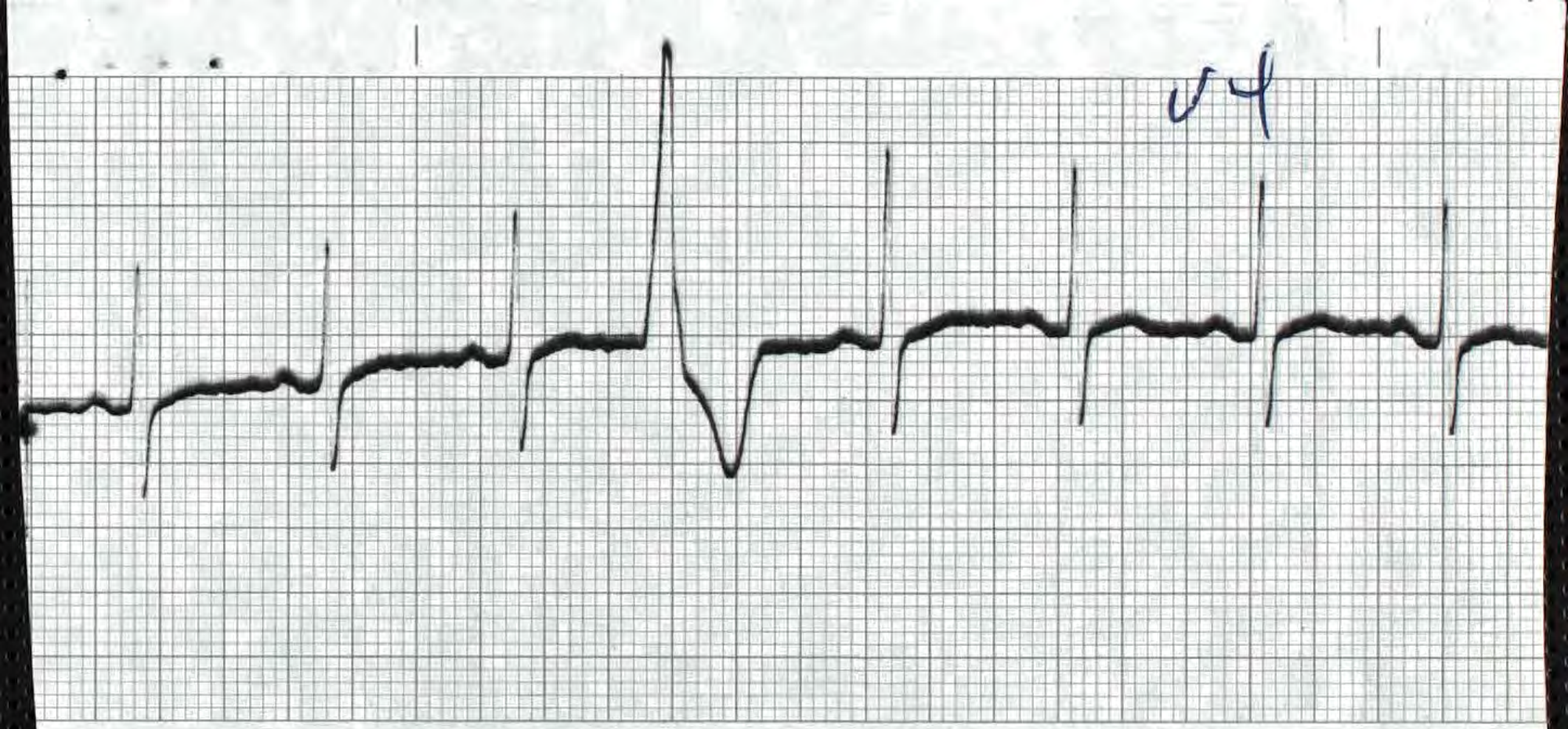
V4


V5

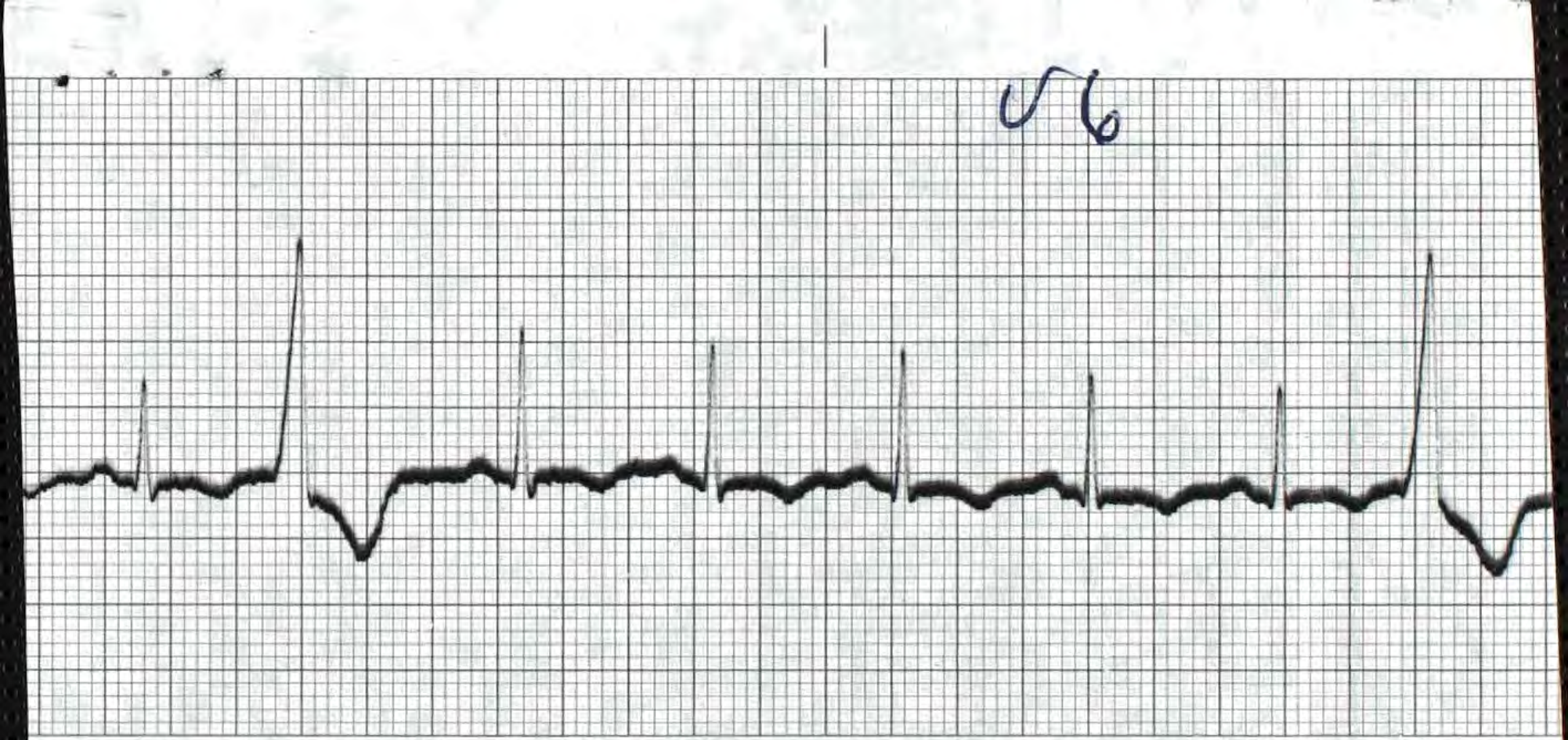

SANBORN VISO-CARDIETTE *Permapaper*

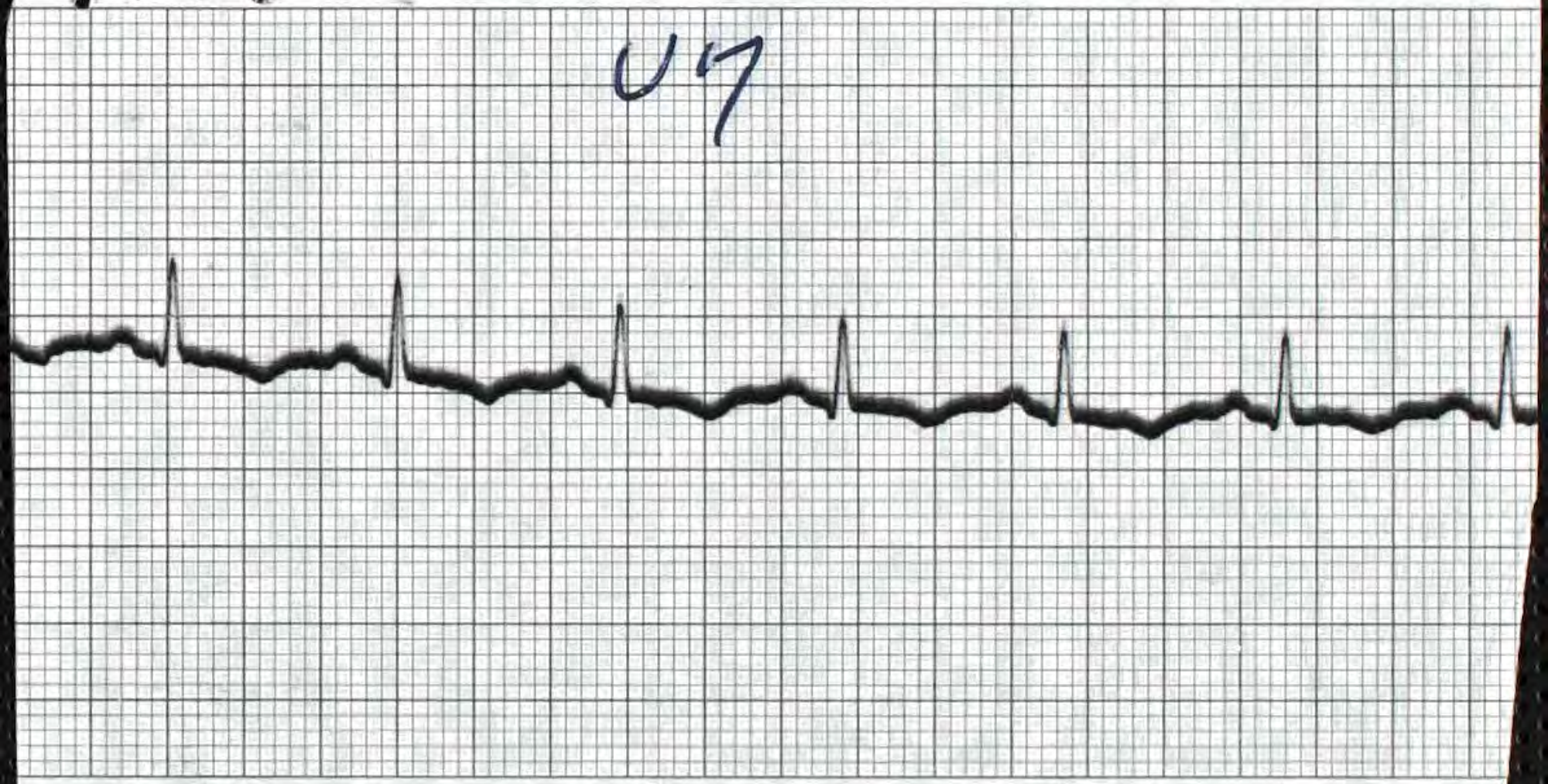

SANBORN VISO-CARDIETTE *Permapaper*


aVR
aVL
aVF
V1
SANBORN VISO CARDIETTE Pathmaker
SANBORN VISO CARDIETTE Pathmaker
SANBORN VI

5915
SZILARD, LEO (PHD)
3-18-58

Dr. Leo Szilard

2-26-58

Lead I

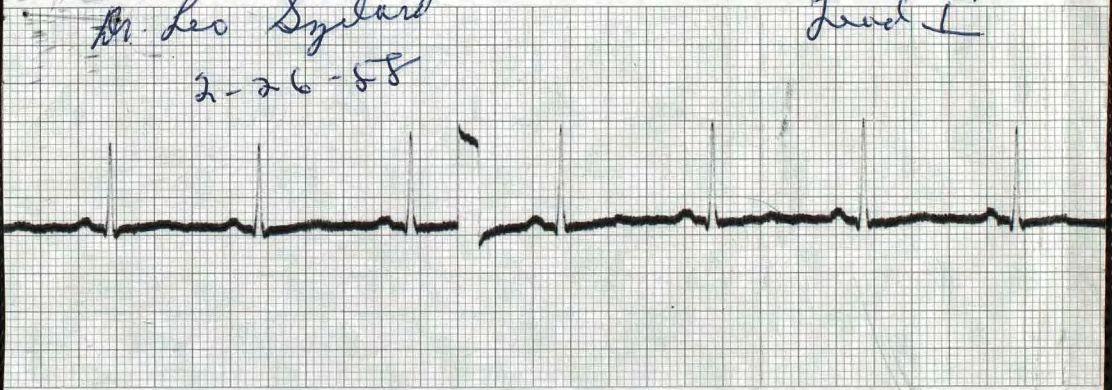

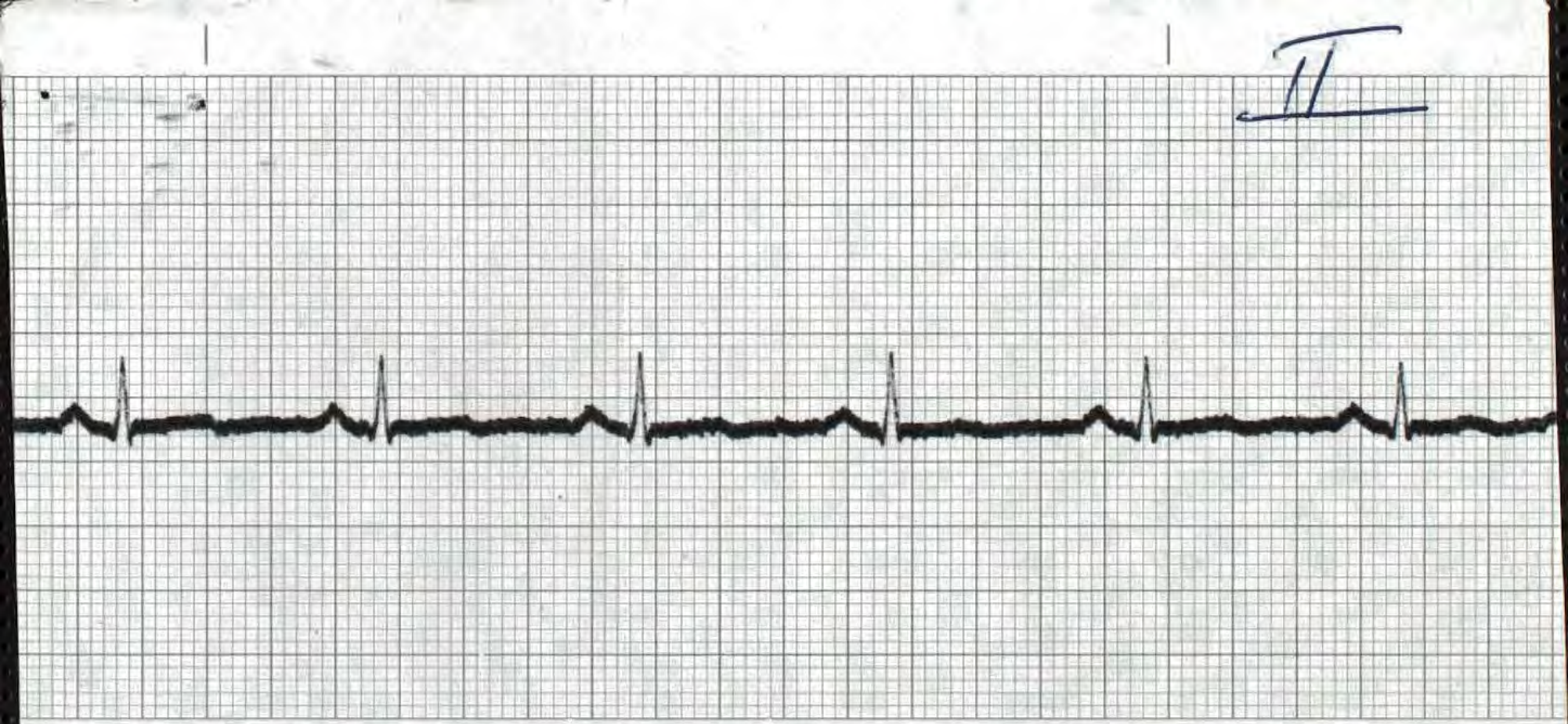
II

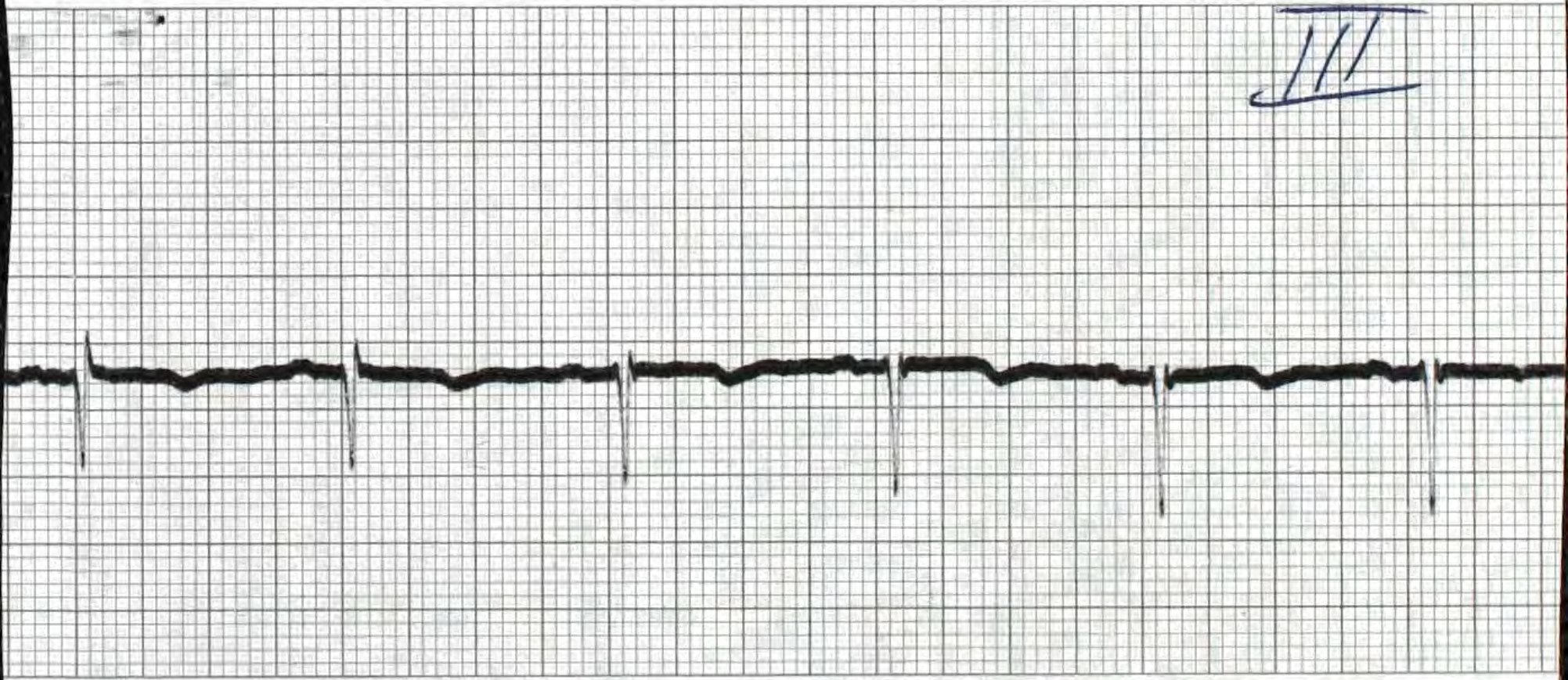

SANBORN VISO-CARDIETTE *Permapaper*

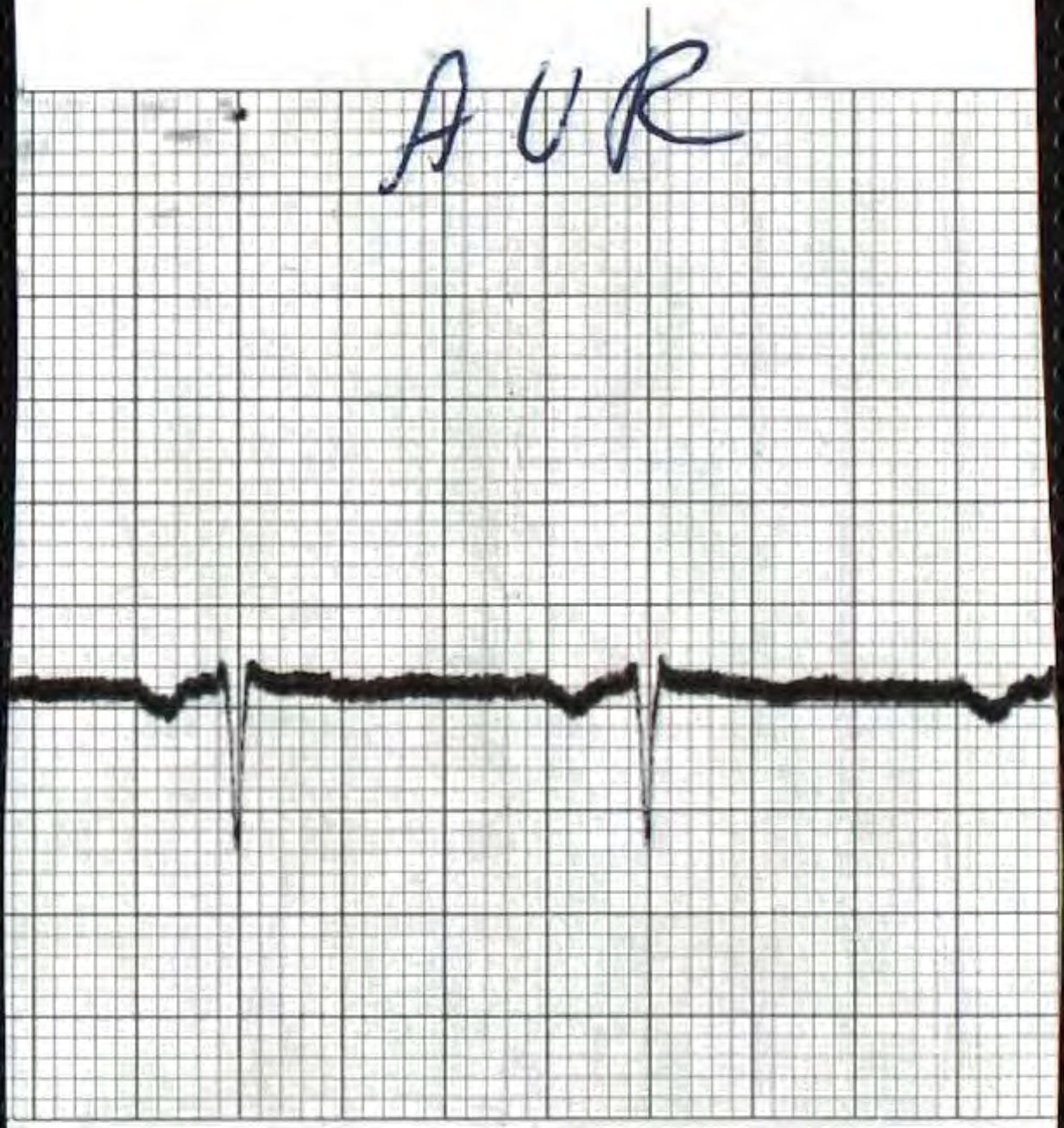
AVR

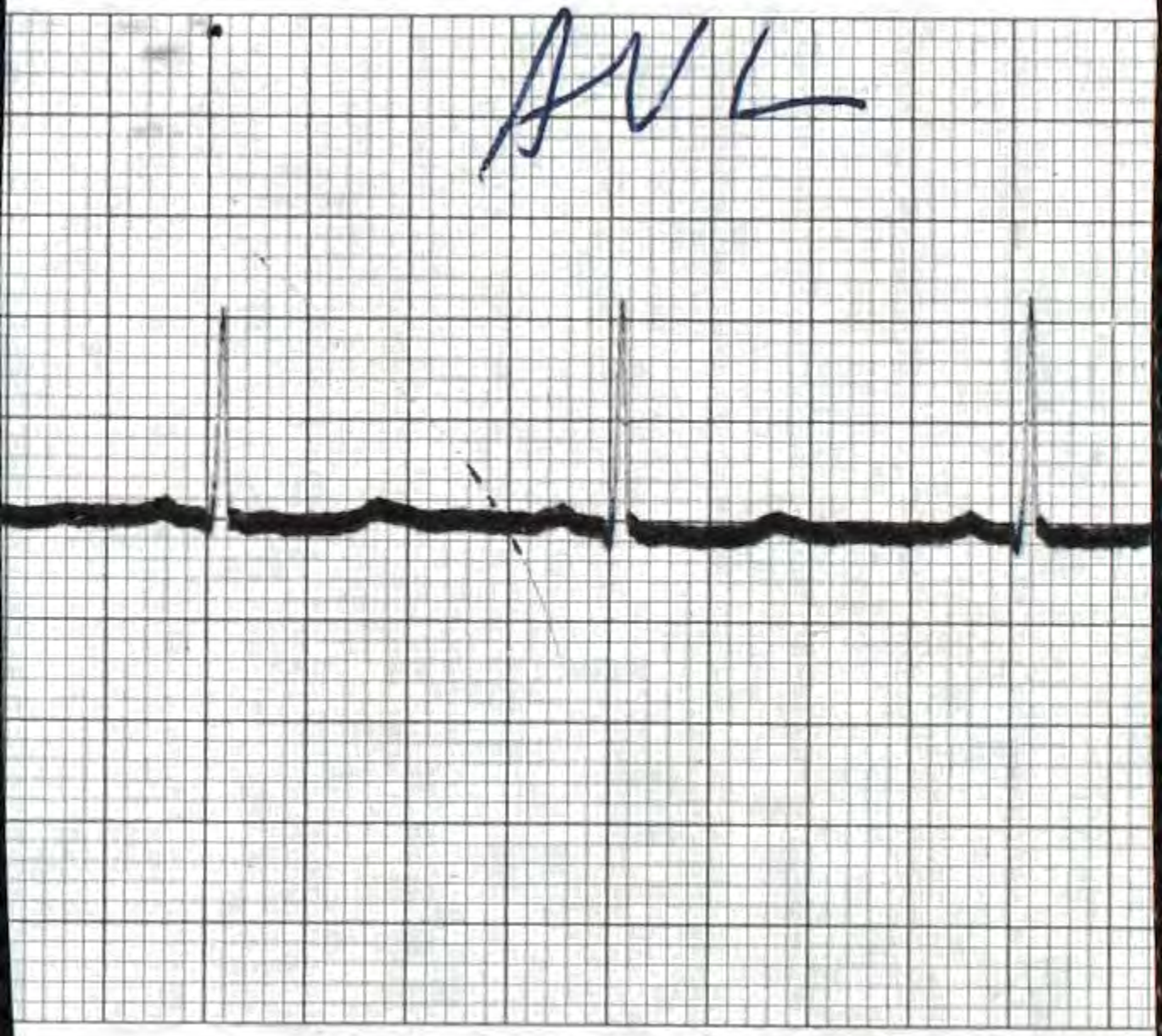
aVL

SANBORN VISO-CARDIETTE *Permapa*

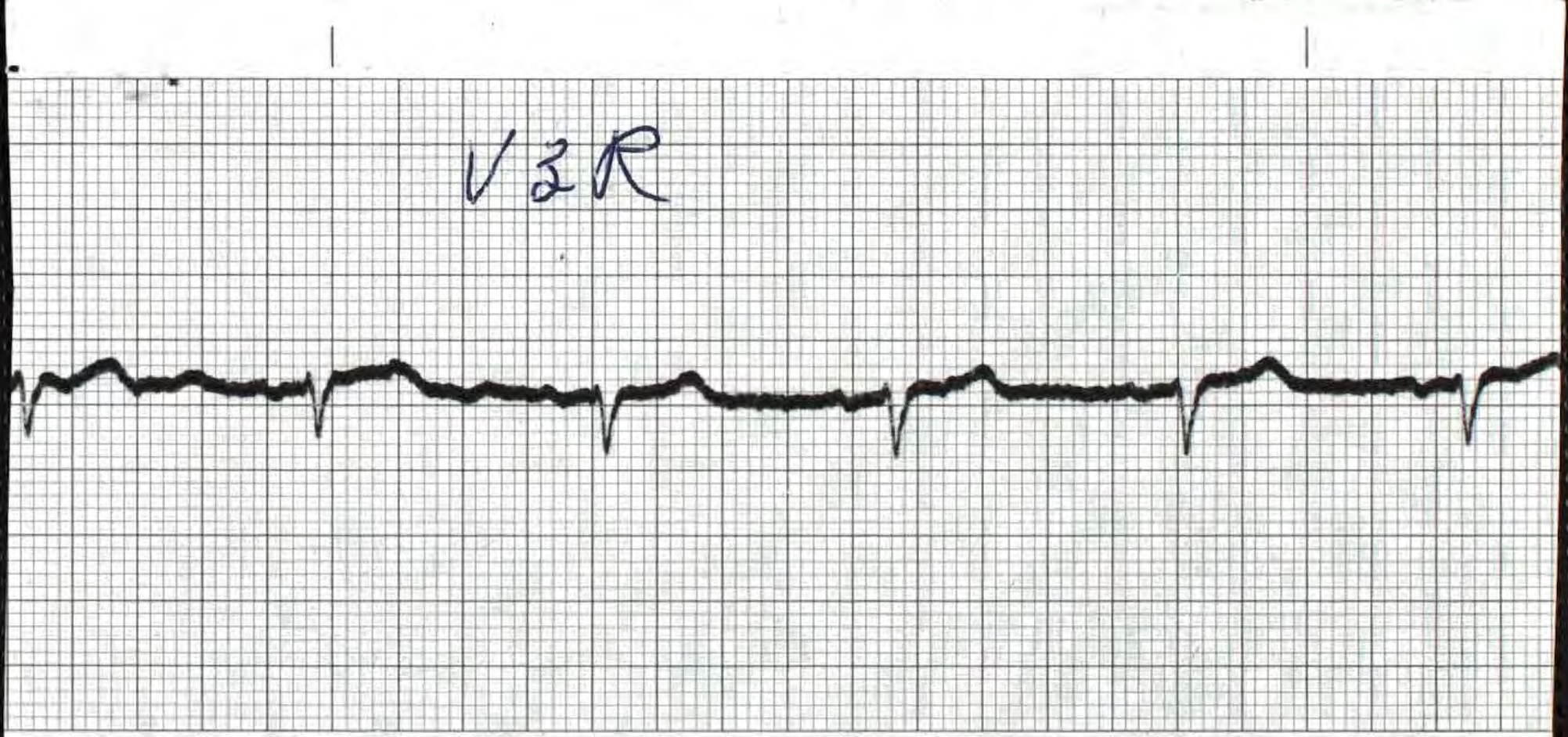
V2R


V1

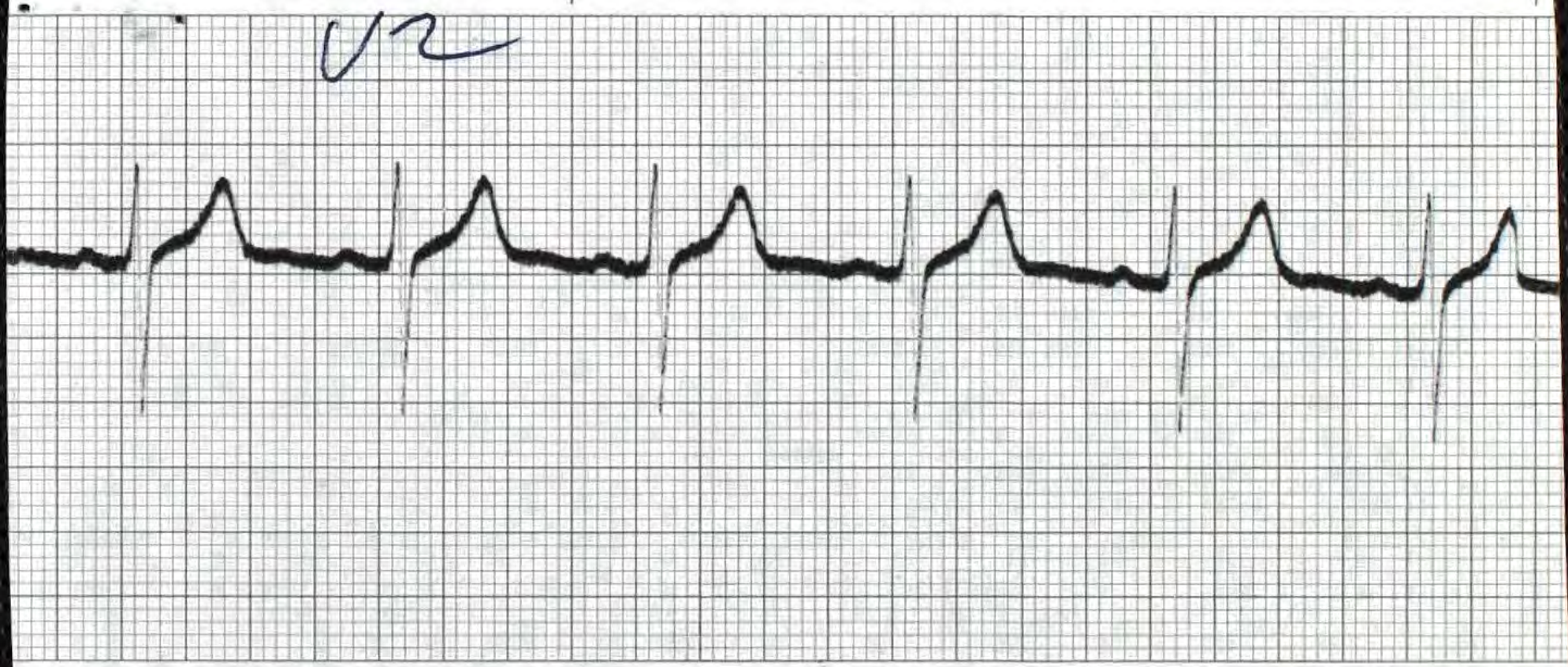
V2

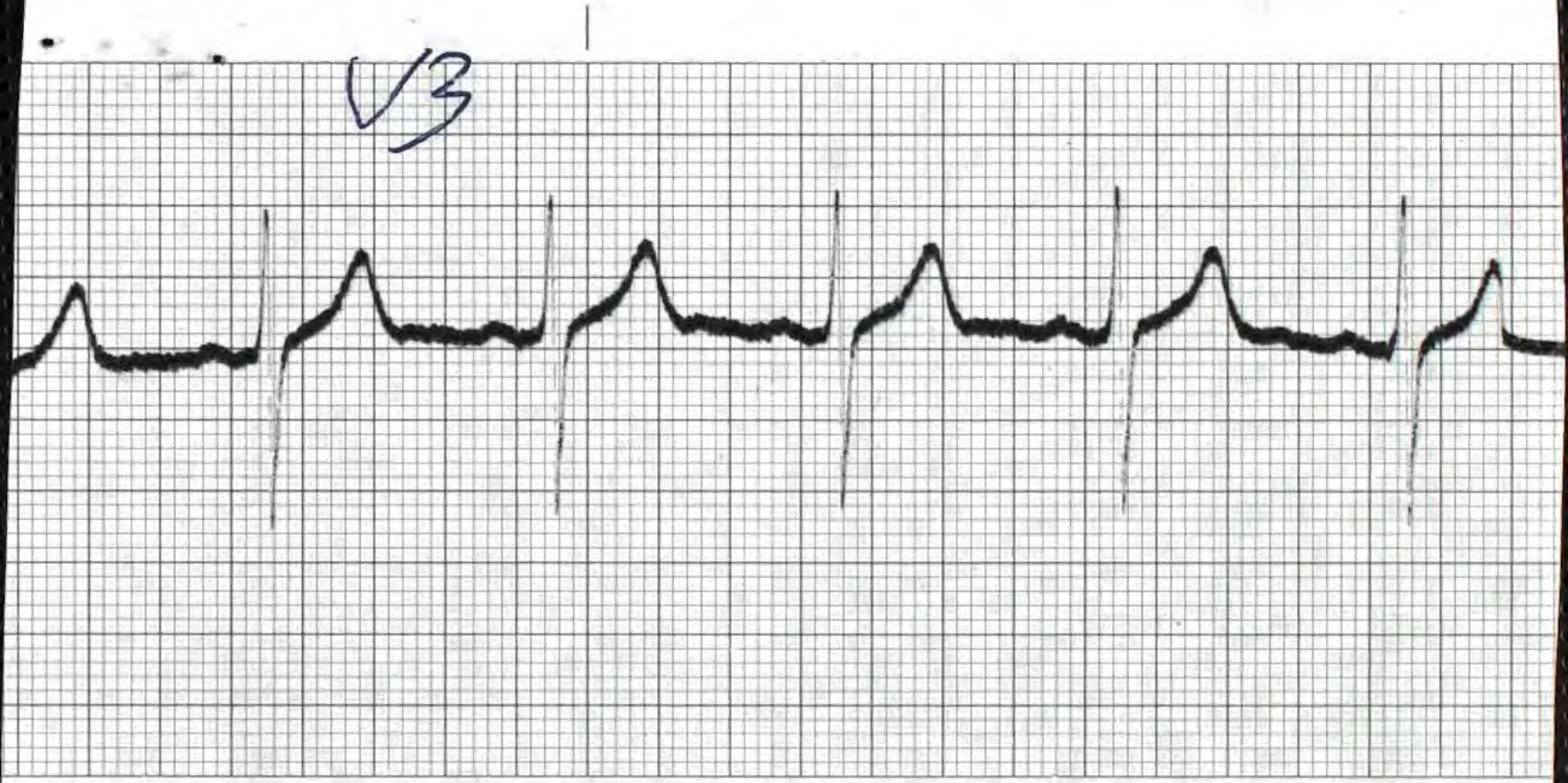
V3

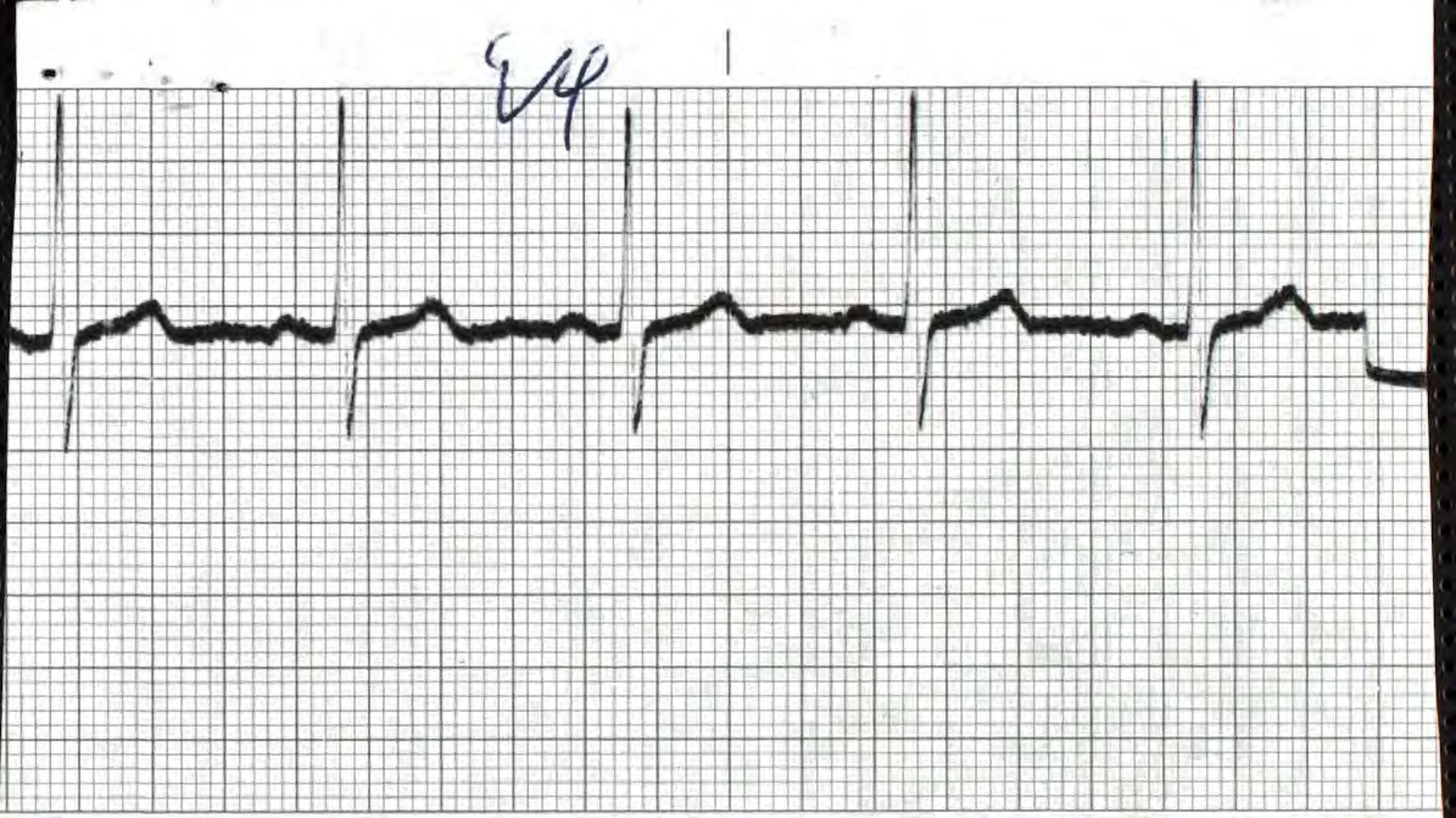

SANBORN VISO-CARDIETTE Pe

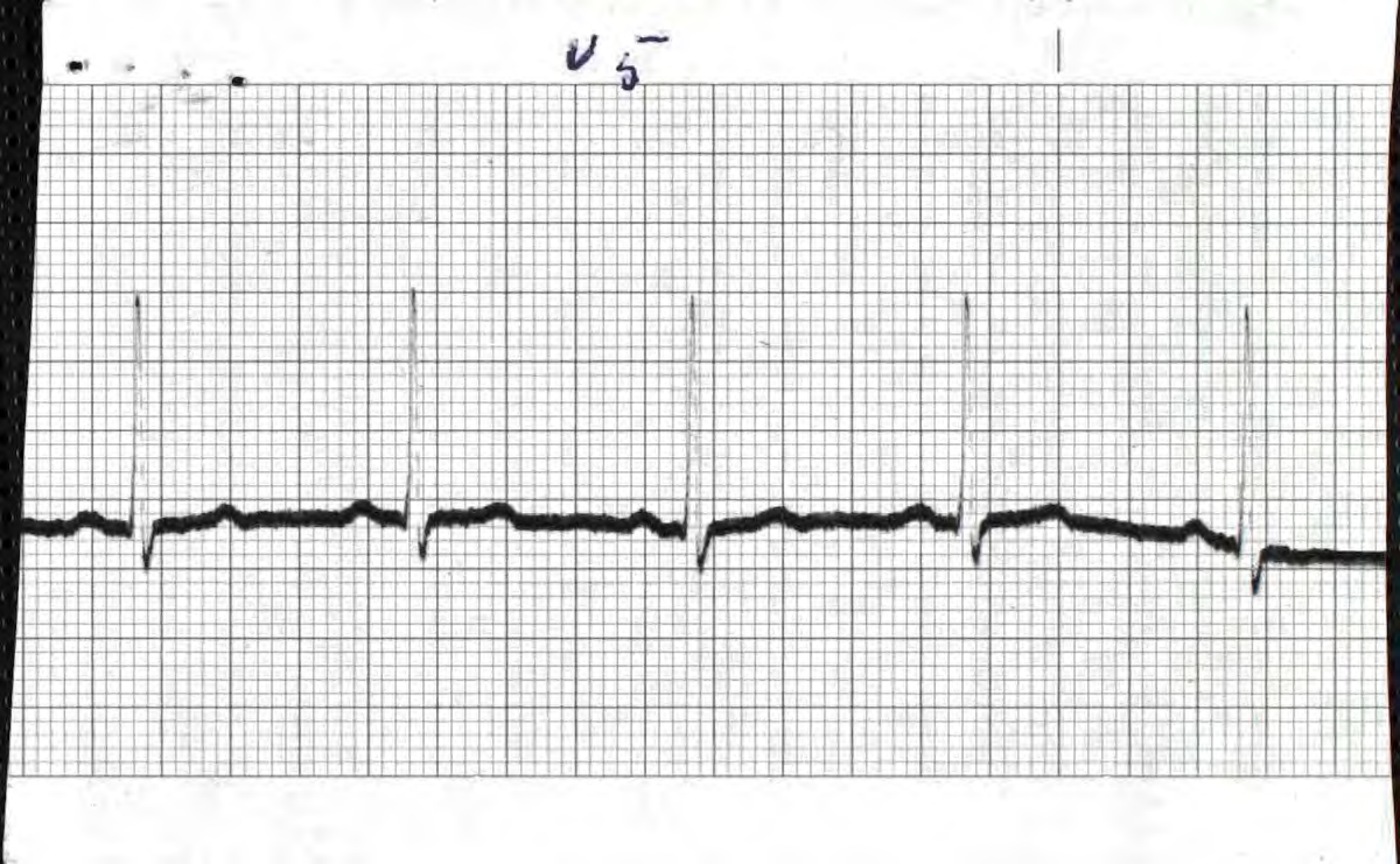
V5

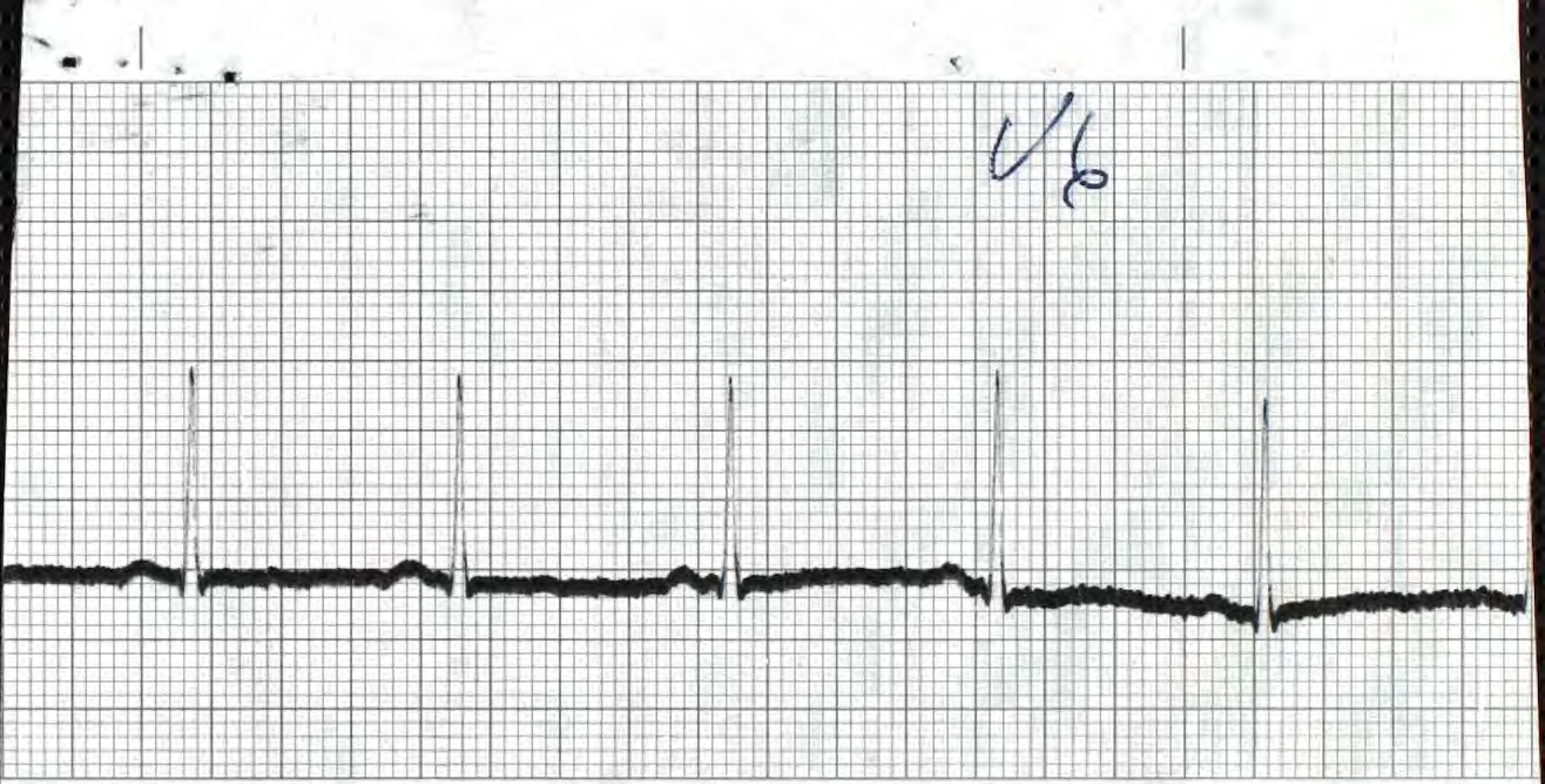

SANBORN VISO-CARDIETTE *Permapaper*


V7

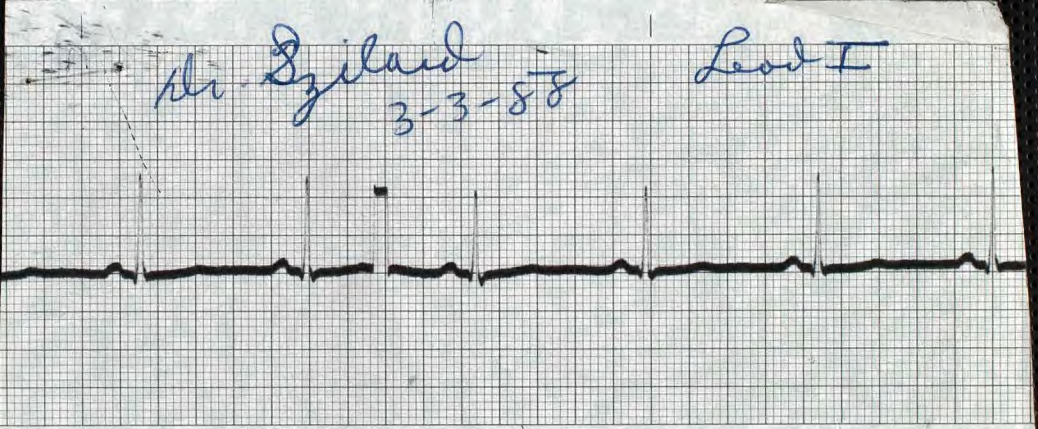

SANBORN VISO-CARDIETTE Por


II

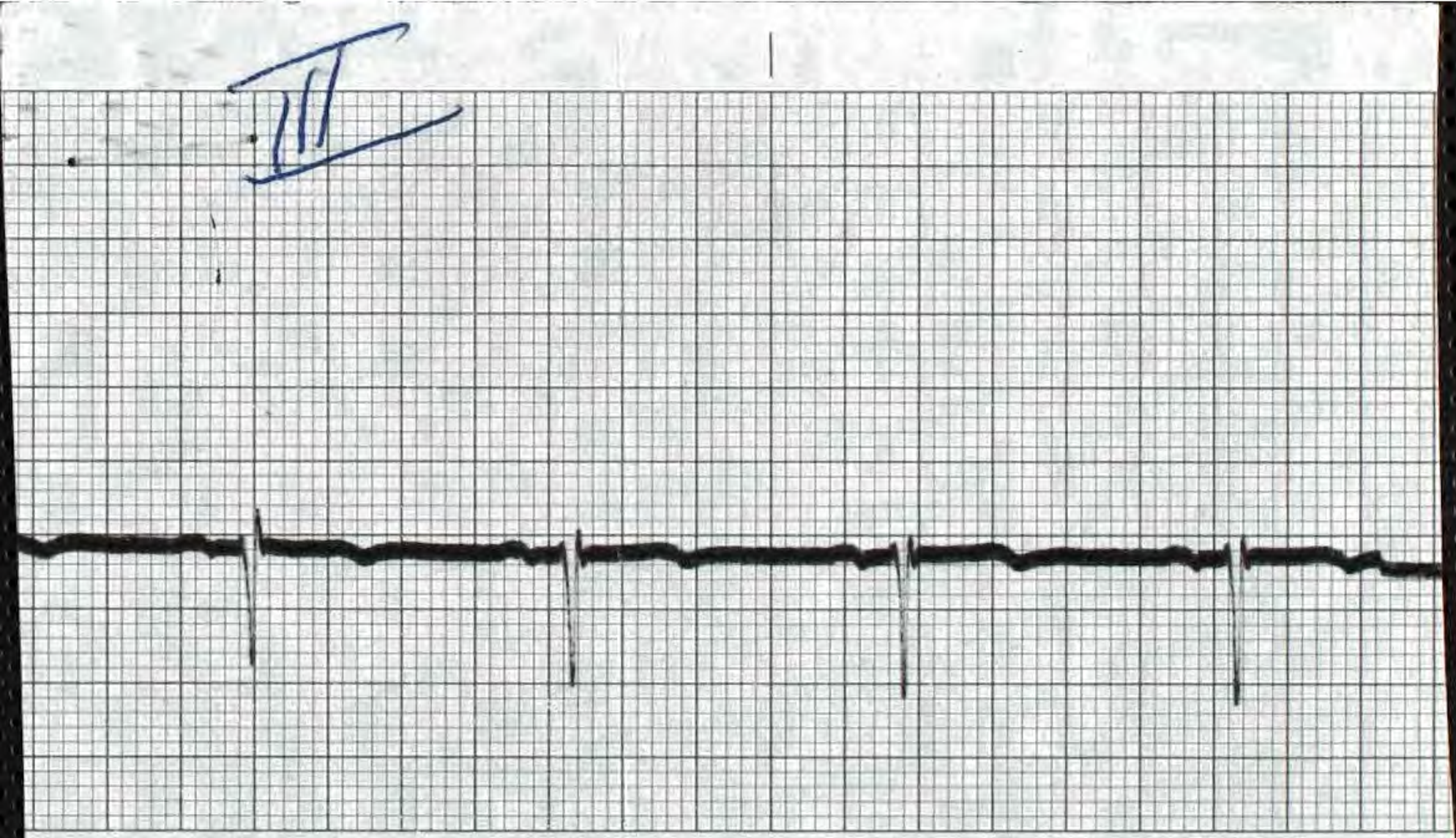

VISO-CARDIETTE *Permapaper*

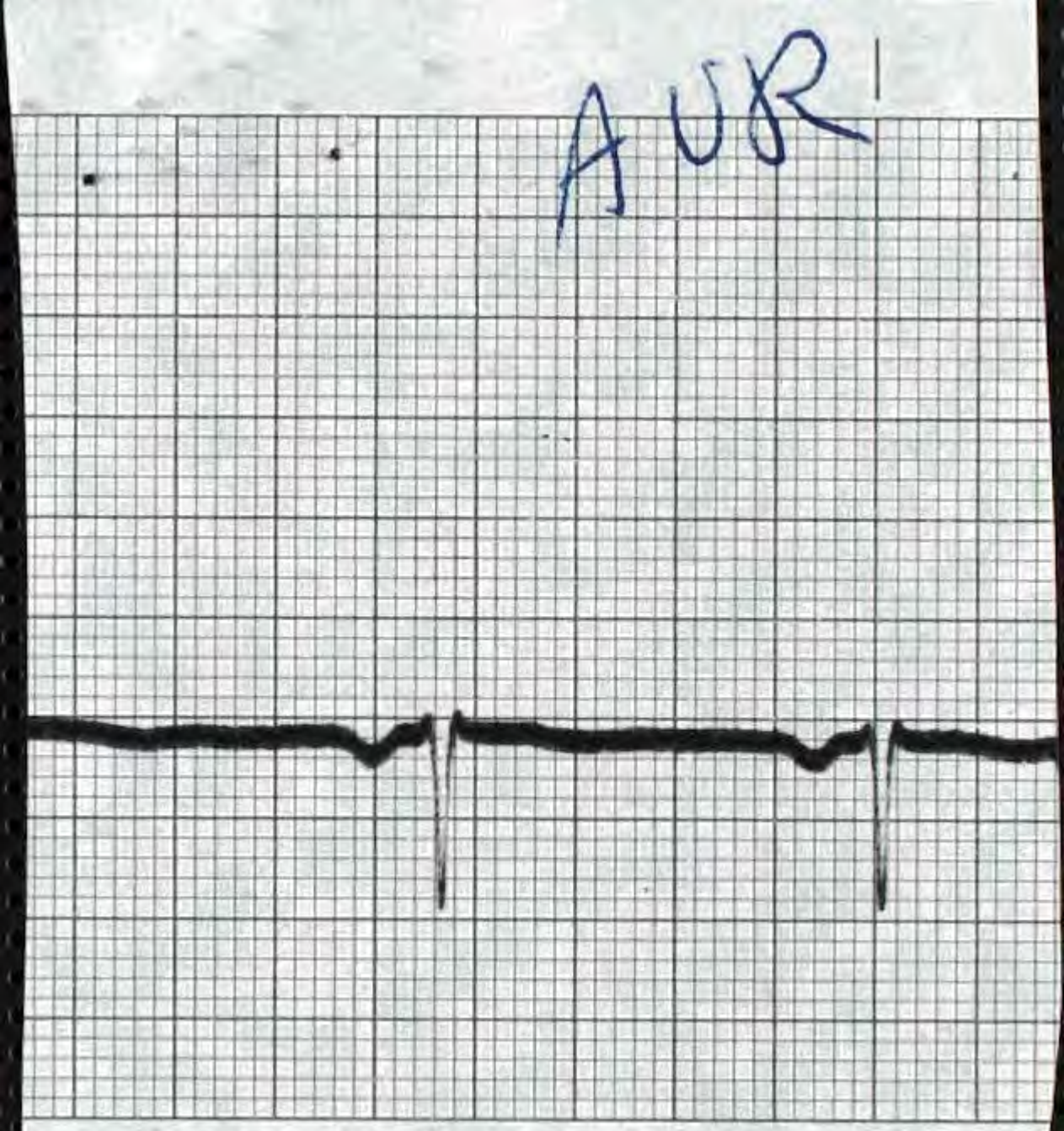
AVR

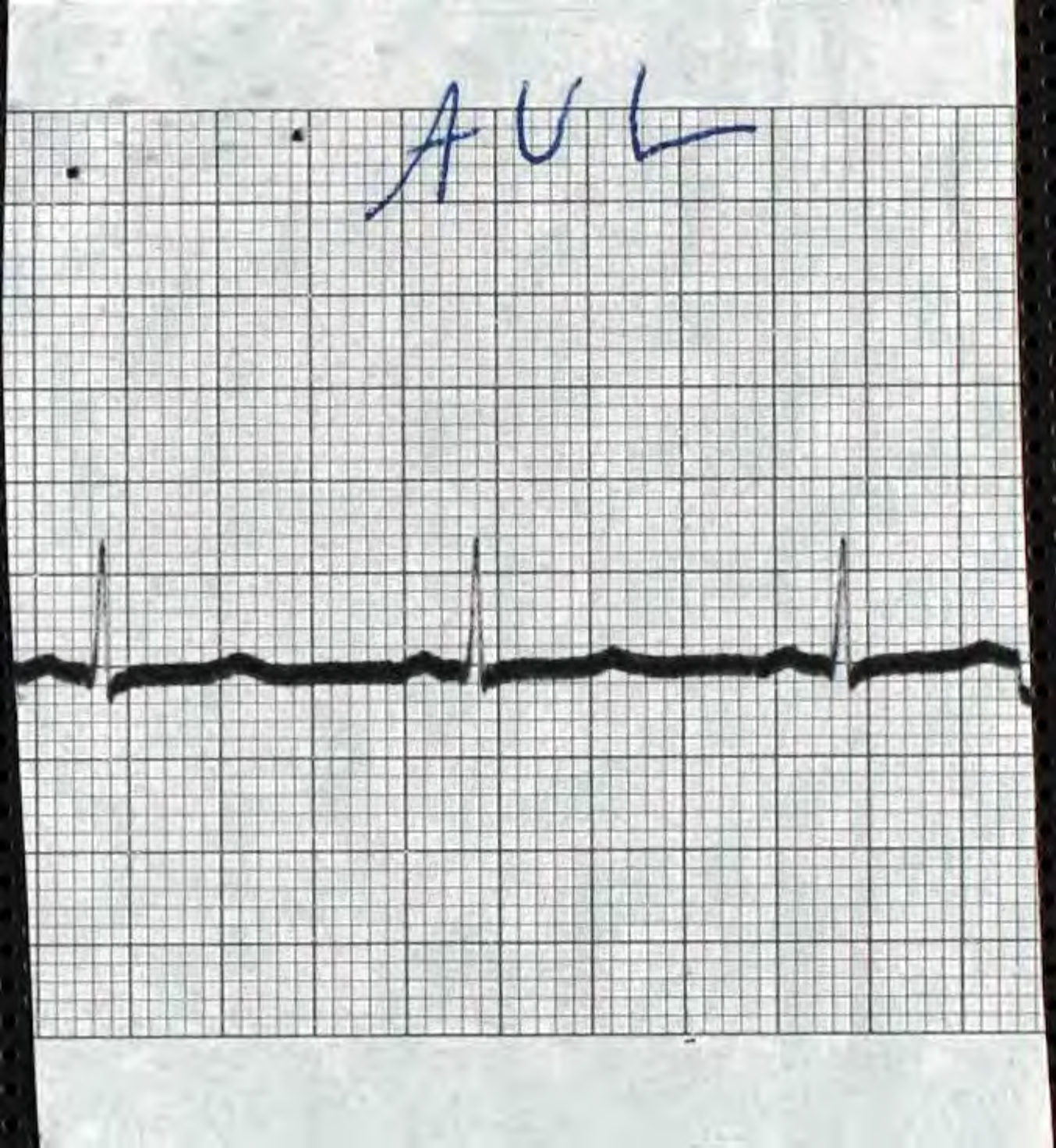
AVL

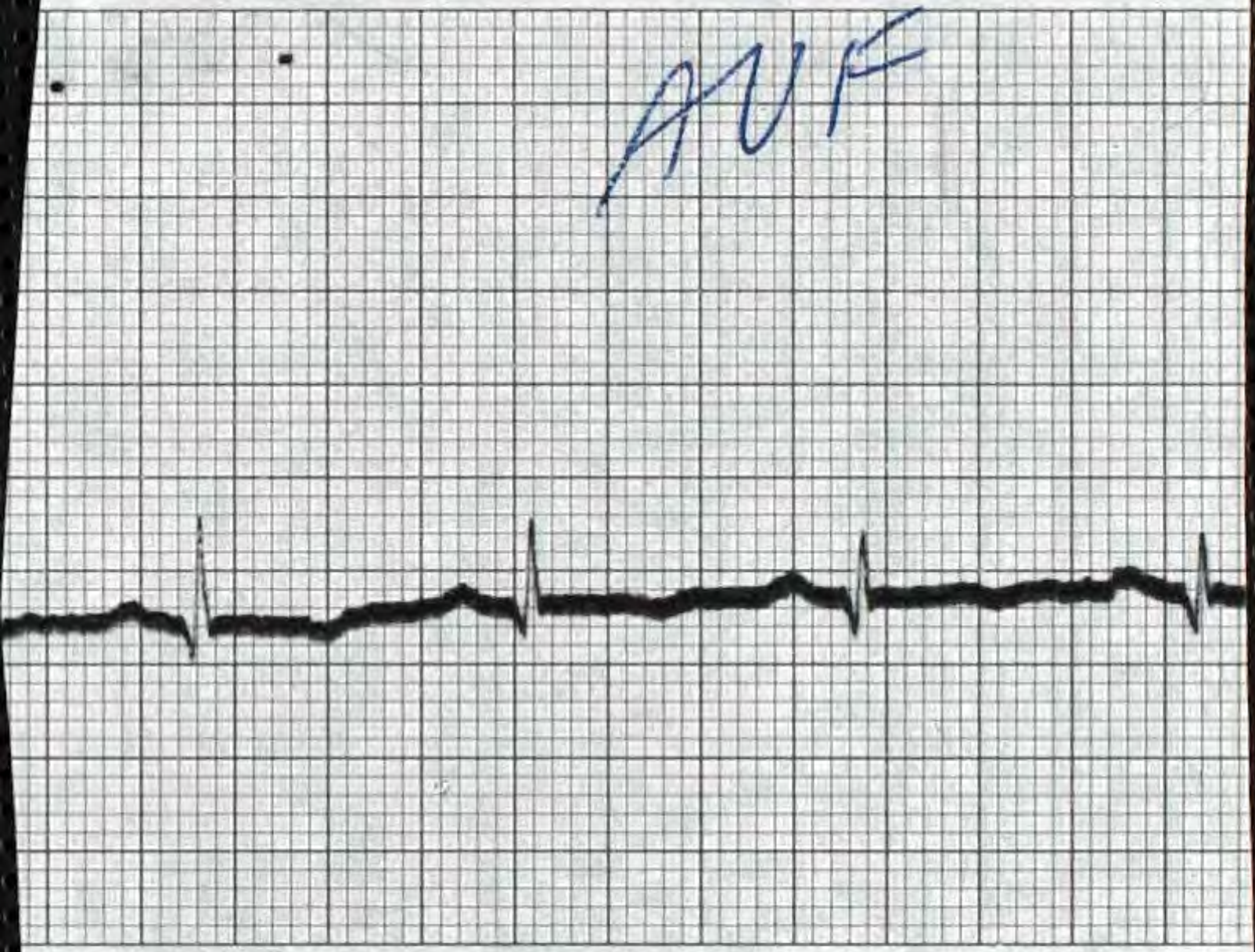

SANBORN VISO-CARDIETTE *Permapaper*

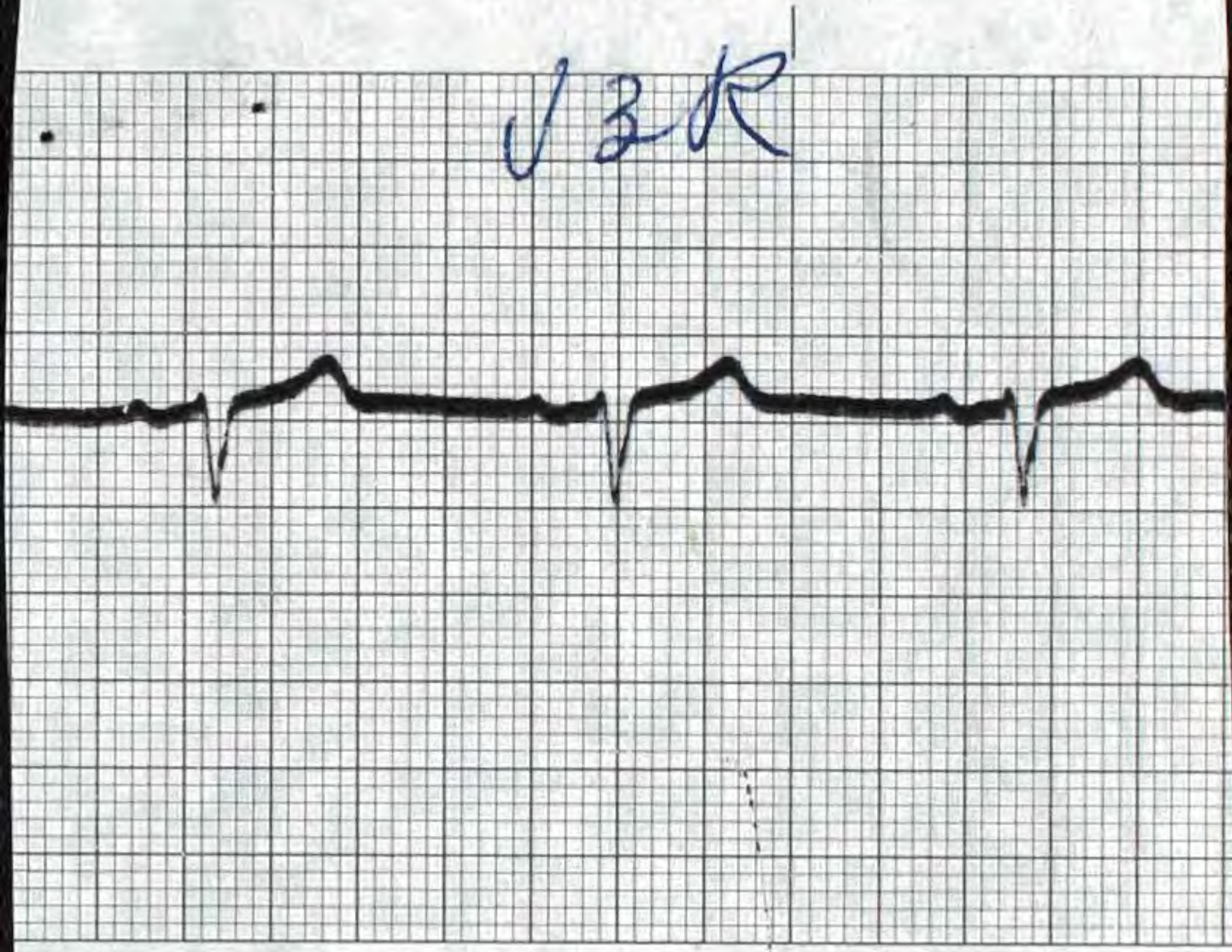
V3R


V1


V2
SANBO

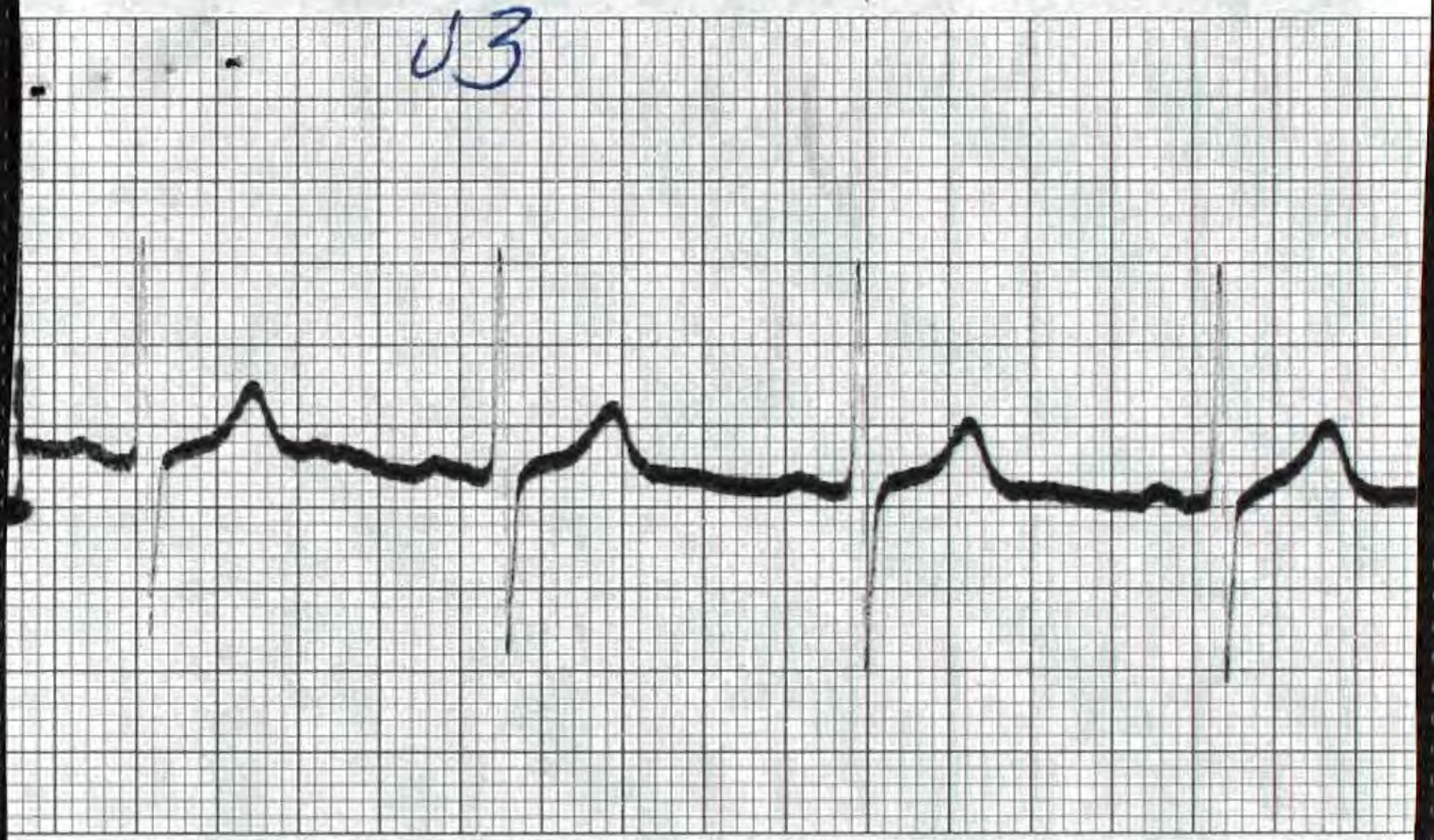

RN VISO-CARDIETTE *Permapaper*

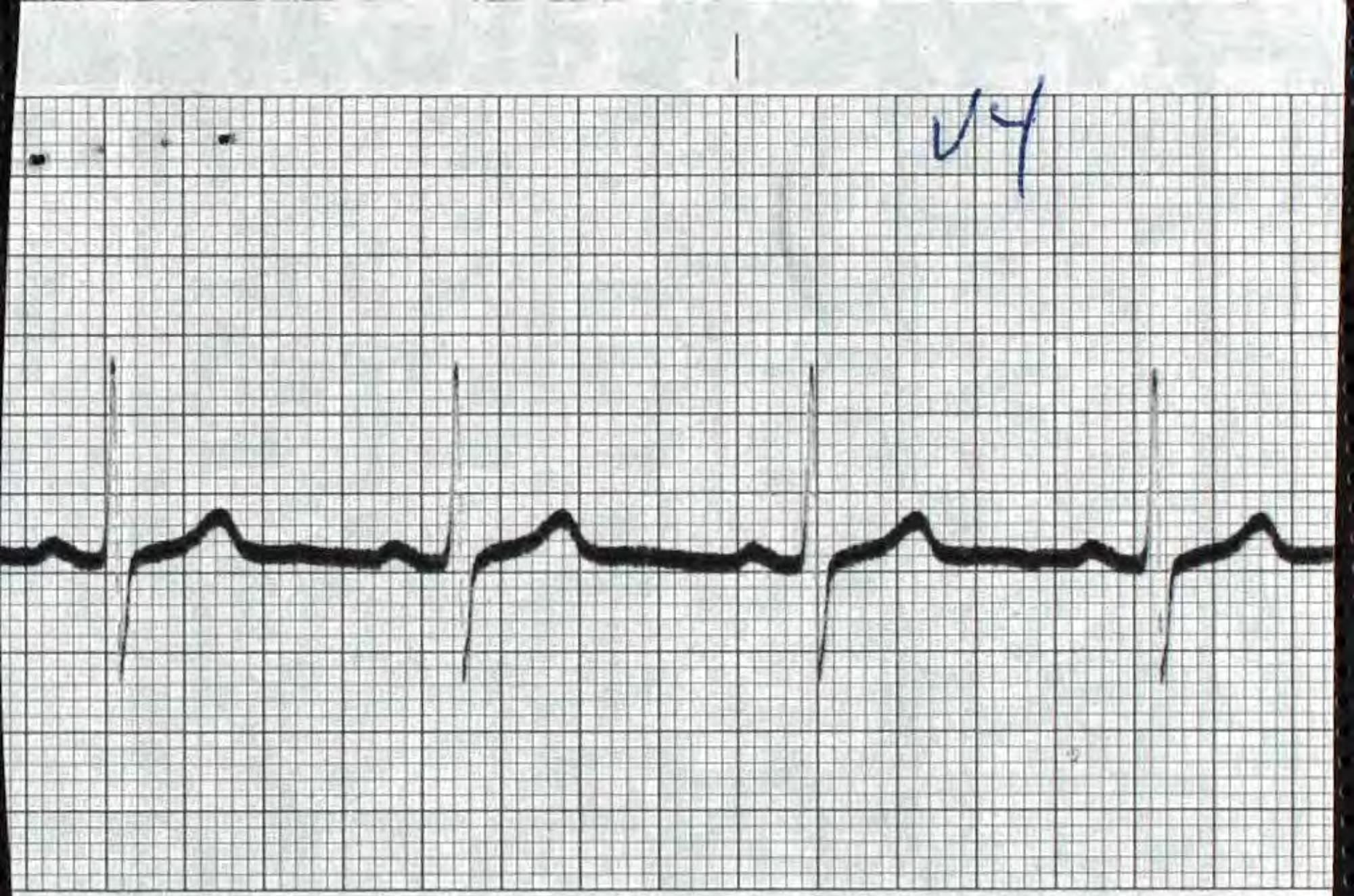
V4
SANBORN VISO-CARD

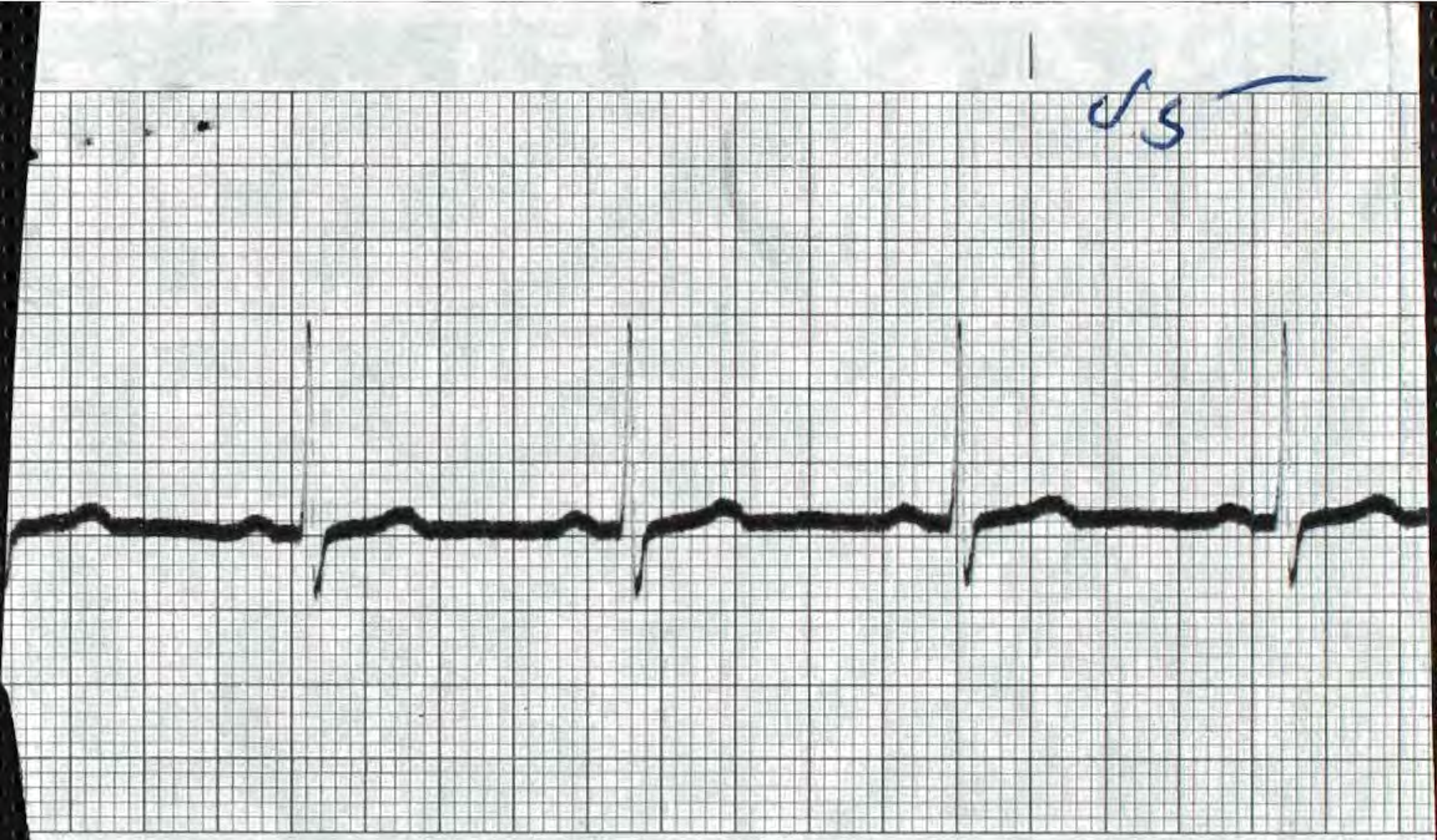
V5

SANBORN VISO-CARDIETTE *Permapaper*

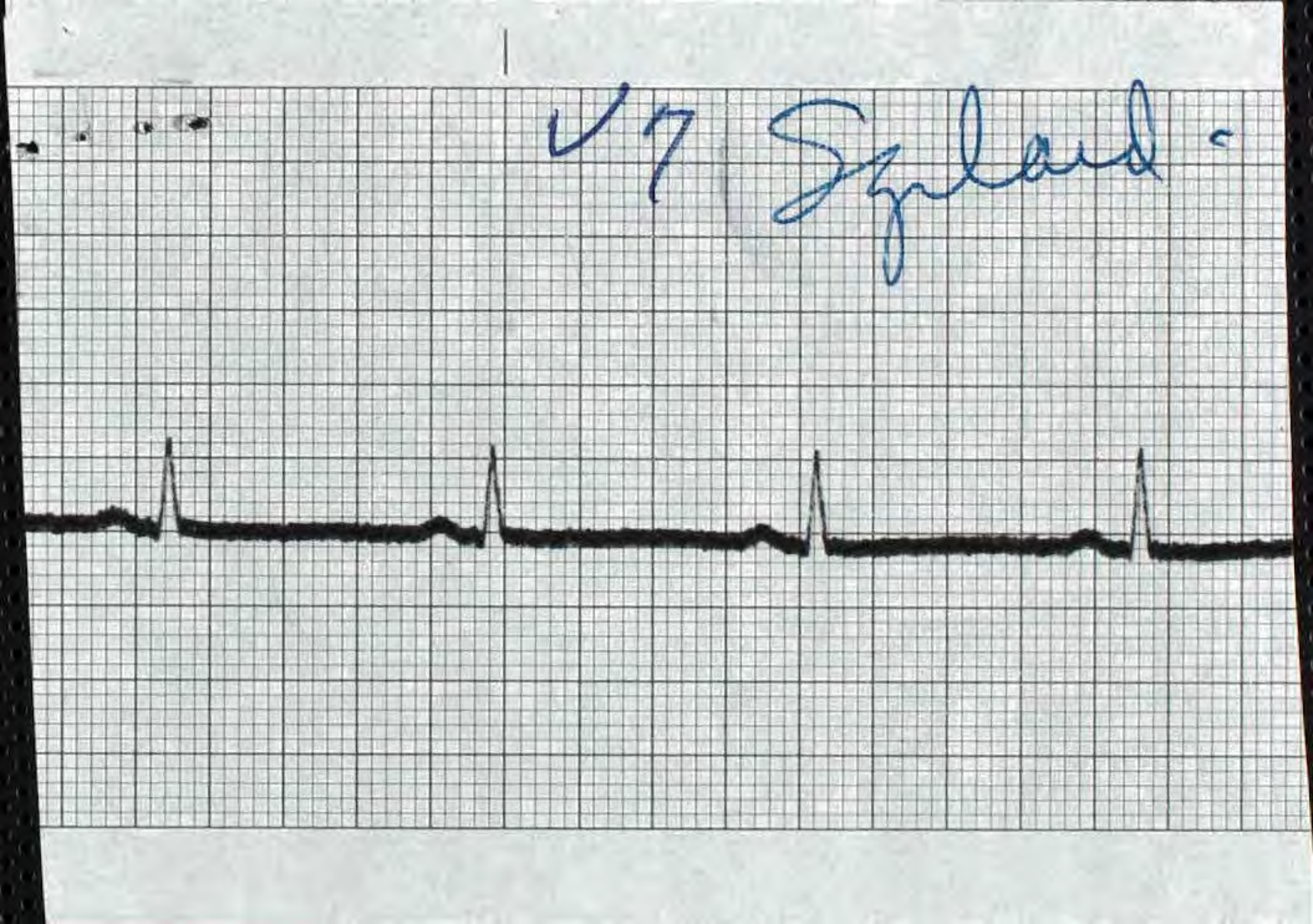
V7 Signal:

MEMORIAL HOSPITAL
444 EAST 68th STREET
NEW YORK CITY 21, N. Y.

SZILARD, LEO DR.

ADMISSION DIAGNOSIS: Ca. of Bladder

DISCHARGE DIAGNOSIS: Ca. of Bladder, post radiation therapy

ADMITTED: 1/7/60

PAST HISTORY: Not remarkable except for history of mild hypertension, EKG changes, suggestive coronary disease in 1957, latent diabetes for thirty years.

PRESENT ILLNESS: Two and a half years ago frequency and urgency in hematuria two years ago. Saw physicians-diagnosis of inflammatory disease was made. June, 1959-cystitis, August, 1959-IVP showed filling defect in bladder. In December, in New York Hospital, patient had a super pubic cystostomy and fulguration for two bladder tumors, one near the dome and the other in the trigone.

After consultation and discussion patient transferred here.

PHYSICAL EXAMINATION: Not remarkable. Patient is moderately obese. A cystostomy wound is present in the left lower quadrant, no evidence of neoplastic disease is found on physical examination.

COURSE IN HOSPITAL: Patient seen by Dr. Whitmore who was asked to assume responsibility for genital urinary management. His initial course was marked by some cystitis which intermittently recurred but responded to appropriate antibiotics.

Cystoscopy on January 25th showed contracted spastic, difusely erythematous, edematous bladder mucosa. Neoplasm could not be distinguished from inflammatory process. Treatment to pelvis, including bladder primary began 1/9/60 and was completed 2/13/60 with maximum bladder dose of 5,300 r, minimum dose 4,500 r at 6cm. and 8.5cm. respectively. Patient tolerated treatment well. There was some proctitis and consequent diarrhea during the latter part of treatment, which subsided several weeks after completion of treatment.

Seriotum examinations of the bladder, including cystoscopy, were not markedly contributory following patient's cours. Papanicolau were done throughout treatment, and have been done at periodic intervals throughout his stay in hospital. These became negative shortly after completion of treatment and have remained negative through the last specimen which was obtained in the mid-portion of November.

MEMORIAL HOSPITAL
444 EAST 68th STREET
NEW YORK CITY 21, N. Y.

Initially, the plan of treatment called for exploratory laparotomy and possible cystectomy following radiation. However, patient in the end did not accept this advice. Consequently, the operative procedure was not done. In late July a filling defect was found on cystogram which was in the base of the bladder; however, on the side opposite to the appearance of the initial lesion. Subsequent studies have showed decrease in the size of this mass. It is not now believed to be related to his neoplasm, but rather to a subacute inflammatory process.

Condition at time of discharge is excellent.

DISCHARGE DIAGNOSIS: Ca. of Bladder, post-operative, quiescent;
Secondary Diagnosis: Diabetes, nominally controlled by diet.
Obesity-moderate

To be followed in Dr. Nickson/Dr. Whitmore's office.

J.J. NICKSON/goc

MEMORIAL CENTER

ELECTROCARDIOGRAPH REPORT

Name SZILARD, DR. LEO 21-02-93 Room No. 812

Address

Date Taken June 7, 1960 EKG No. 30307 Position: Recumbent ☐ Semi-Recumbent ☐

Rhythm Normal sinus rhythm

Electrical Axis Left axis deviation Auricular rate 92 Ventricular rate 92

P-R (A-V) O. 16 sec. (QRS (I—V) O. 06 sec. Q-T O. 35 sec.

Interpretation and Conclusions:

Since 6/3/60 Q in ARF less prominent. Low T in I, AVL and V5-6 persist.

Date Reported June 8, 1960 By Irwin Nydick M.D.

IRWIN NYDICK, M.D.

10710

MEMORIAL CENTER

Name [illegible] Date taken 6-7-60 Room No. 812

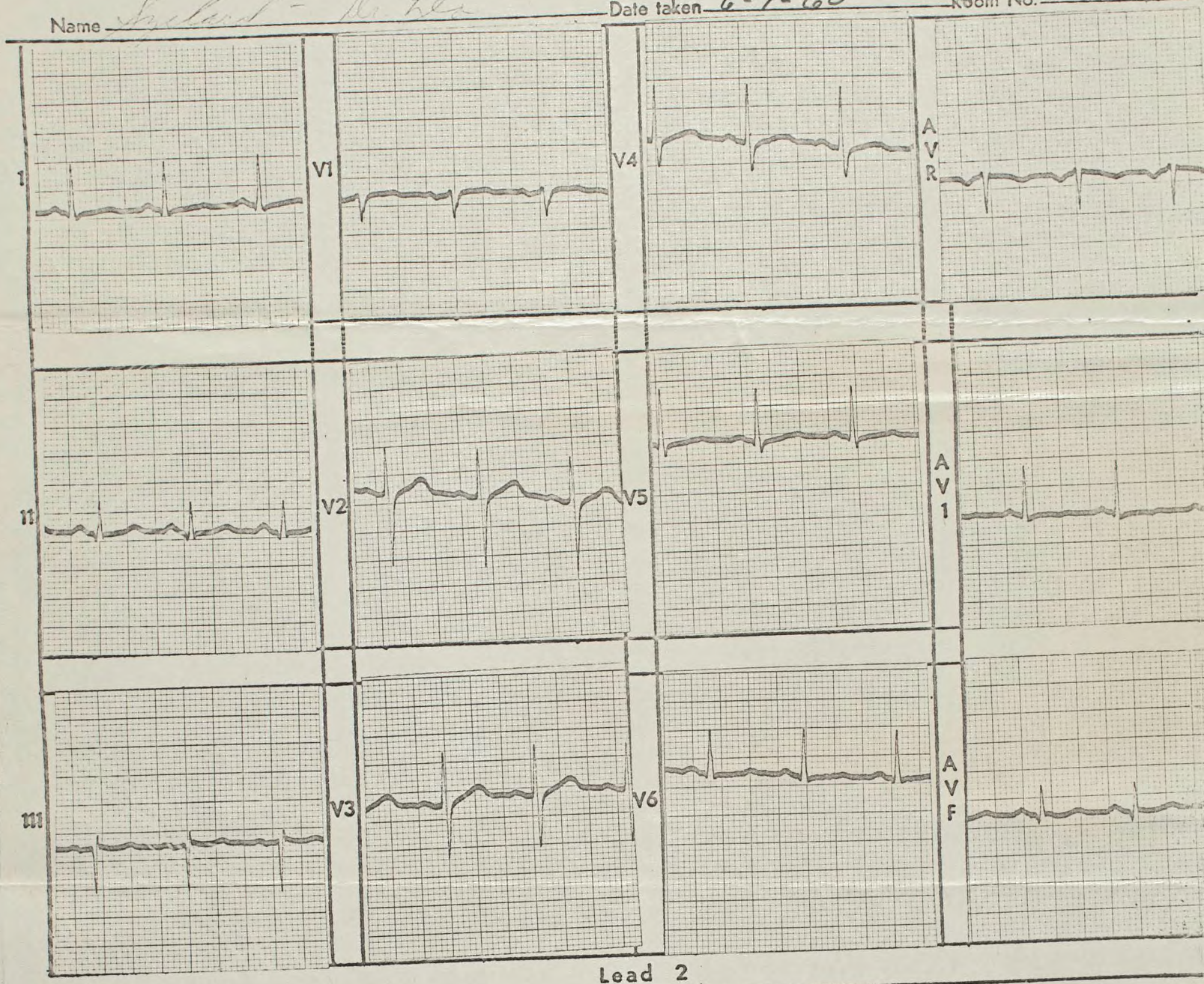

Lead 2

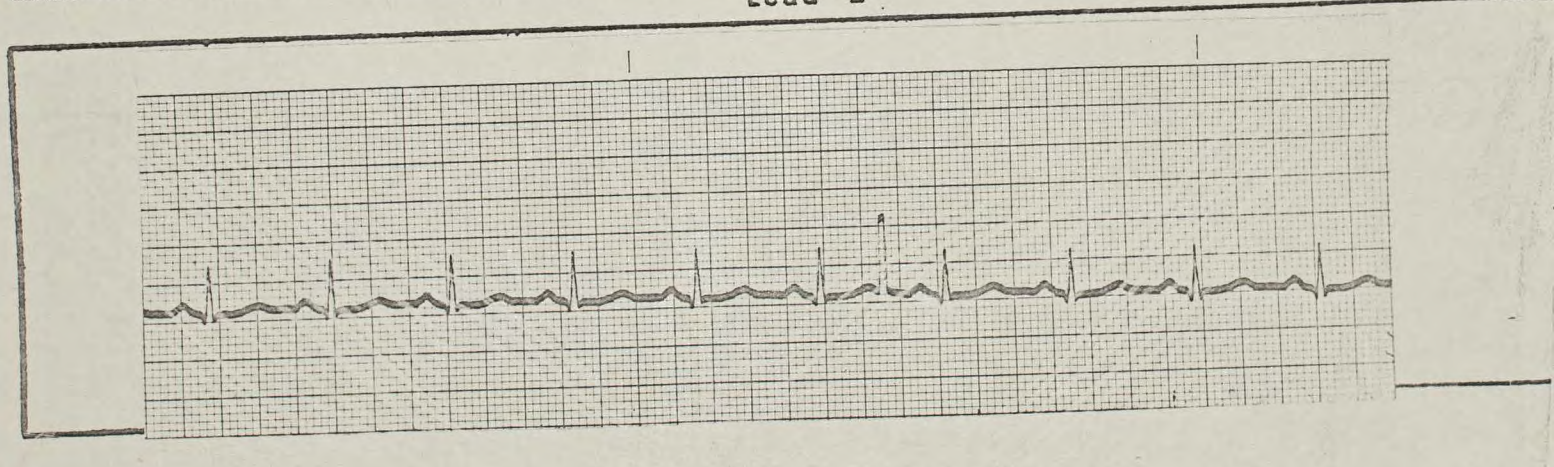

Szilard, Leo (C63-5431) Dr. Whitmore 3/8/63

Catheterized urine specimen of 3/3/63

There are some altered cells in this specimen but they are considered to be of a benign nature.

PMN's are fairly numerous.

Class II

J.F. Seybolt

Papanicolaou Cytology Laboratory

Szilard, Dr. Leo (C61-20458) Dr. Whitmore 10/19/61

Catheterized urine specimen of 10/13/61

No cytologic evidence of a malignant neoplasm is found.

PMN's are numerous.

Class I

J.F. Seybolt
Papanicolaou Cytology Laboratory

Szilard, Leo (C62-4700) Dr. Whitmore 3/7/62

Bladder washing specimen of 2/28/62

There are cells giving some suspicion of a malignant neoplasm but they are inconclusive. PMN's are fairly numerous.

Class III

N. Lowe
Papanicolaou Cytology Laboratory

GROUP HEALTH ASSOCIATION, INC.

1025 VERMONT AVENUE, N.W., WASHINGTON 5, D. C.

TELEPHONE: EXECUTIVE 3-8000

Dr. Szilard urine culture 12-4-61

Pseudomonas aeruginosa

BACTERIAL ANTIBIOTIC SENSITIVITY

ANTIBIOTIC	Sensitive	Moderately Sensitive	Slightly Sensitive	Resistant
PENICILLIN				X
STREPTOMYCIN				X
NOVOBIOCIN (CATHOMYCIN)				X
AUREOMYCIN				X
TERRAMYCIN				X
TETRACYCLINE				X
CHLOROMYCETIN				X
ERYTHROMYCIN				X
~~OLEANDOMYCIN~~ Furadantin				X
~~NEOMYCIN~~ Mandelamine				X
POLYMYXIN B	X			
Triple Sulfa	X			
Gantrisin				X

Proteus vulgaris

BACTERIAL ANTIBIOTIC SENSITIVITY

ANTIBIOTIC	Sensitive	Moderately Sensitive	Slightly Sensitive	Resistant
PENICILLIN				X
STREPTOMYCIN	X			
NOVOBIOCIN (CATHOMYCIN)	X			
AUREOMYCIN				X
TERRAMYCIN				X
TETRACYCLINE				X
CHLOROMYCETIN	X			
ERYTHROMYCIN				X
~~OLEANDOMYCIN~~ Furadantin				X
~~NEOMYCIN~~ Mandelamine	X			
POLYMYXIN B				X
Triple Sulfa				X
Gantrisin	X			

Escherichia coli

BACTERIAL ANTIBIOTIC SENSITIVITY

ANTIBIOTIC	Sensitive	Moderately Sensitive	Slightly Sensitive	Resistant
PENICILLIN				X
STREPTOMYCIN	X			
NOVOBIOCIN (CATHOMYCIN)	X			
AUREOMYCIN	X			
TERRAMYCIN	X			
TETRACYCLINE	X			
CHLOROMYCETIN	X			
ERYTHROMYCIN				X
~~OLEANDOMYCIN~~ Furadantin	X			
~~NEOMYCIN~~ Mandelamine	X			
POLYMYXIN B	X			
Triple Sulfa				X
Gantrisin				X

Aerobacter-Klebsiella group

BACTERIAL ANTIBIOTIC SENSITIVITY

ANTIBIOTIC	Sensitive	Moderately Sensitive	Slightly Sensitive	Resistant
PENICILLIN				X
STREPTOMYCIN	X			
NOVOBIOCIN (CATHOMYCIN)	X			
AUREOMYCIN				
TERRAMYCIN	X			
TETRACYCLINE	X			
CHLOROMYCETIN	X			
ERYTHROMYCIN				X
~~OLEANDOMYCIN~~ Furadantin	X			
~~NEOMYCIN~~ Mandelamine	X			
POLYMYXIN B				X
Triple Sulfa	X			
Gantrisin				X

I

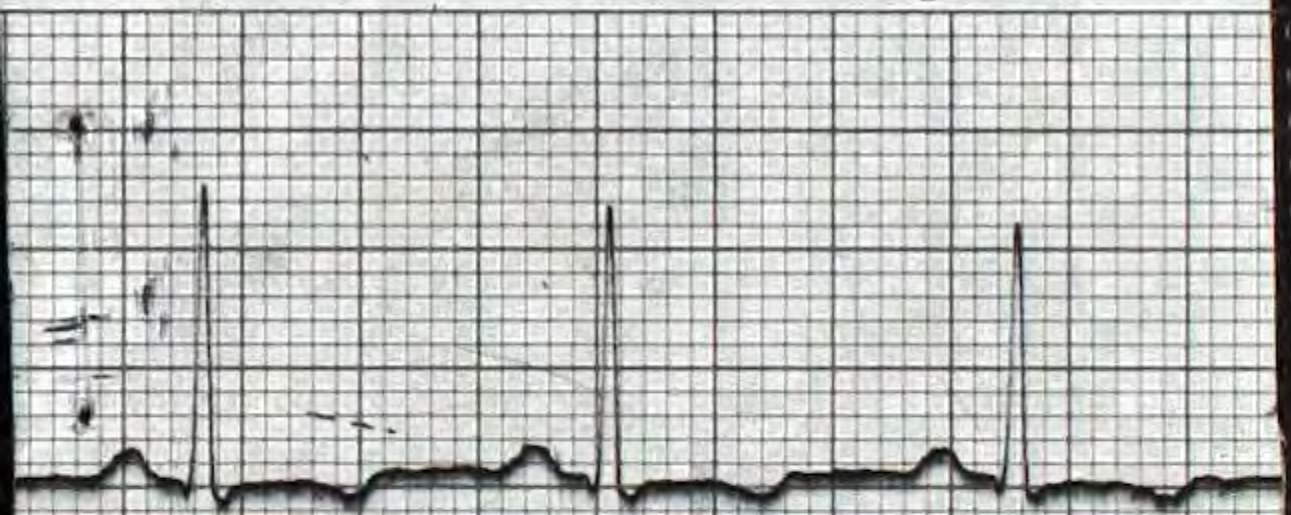

Leo Szilard

4-7-6 v

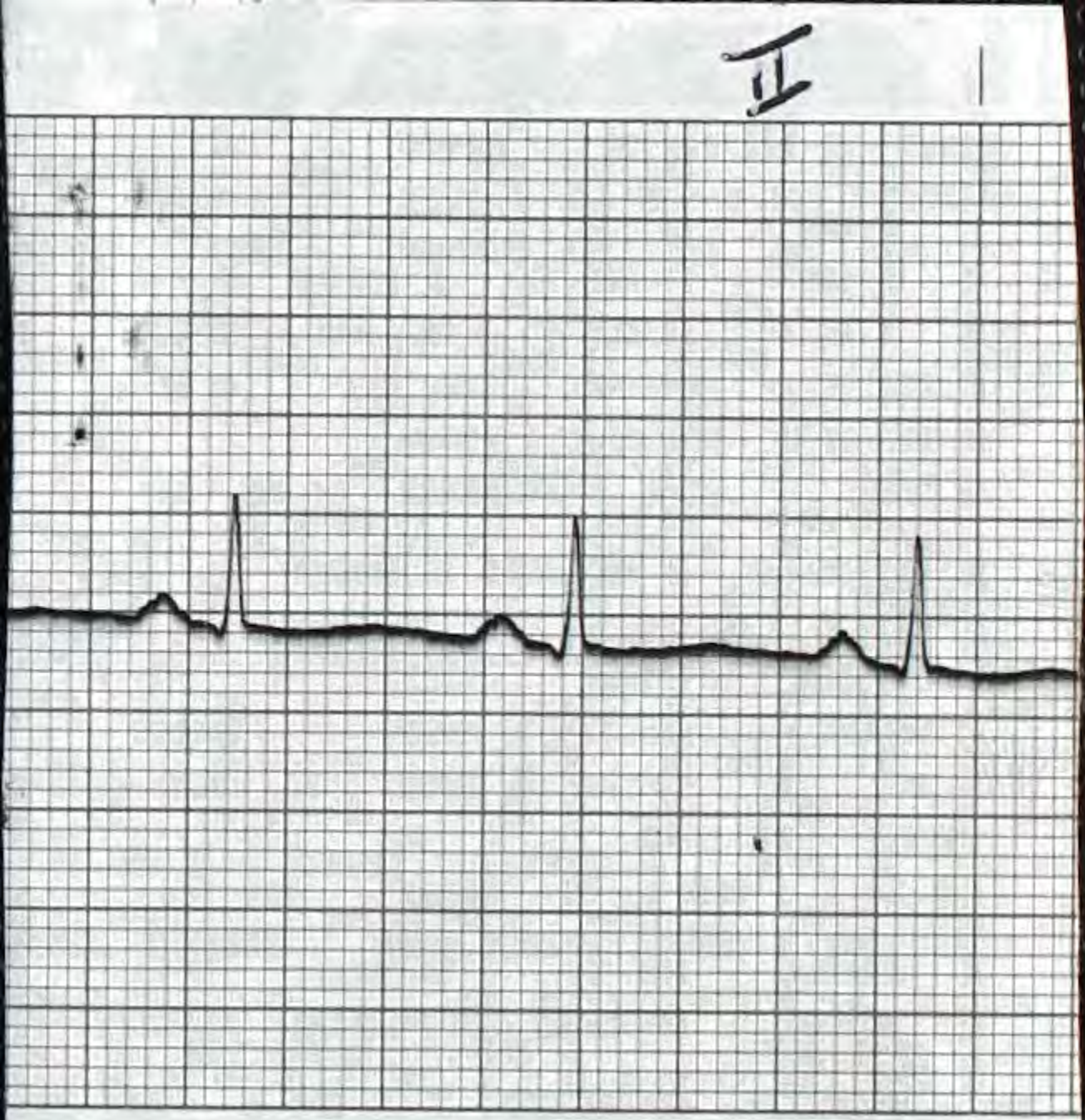
II

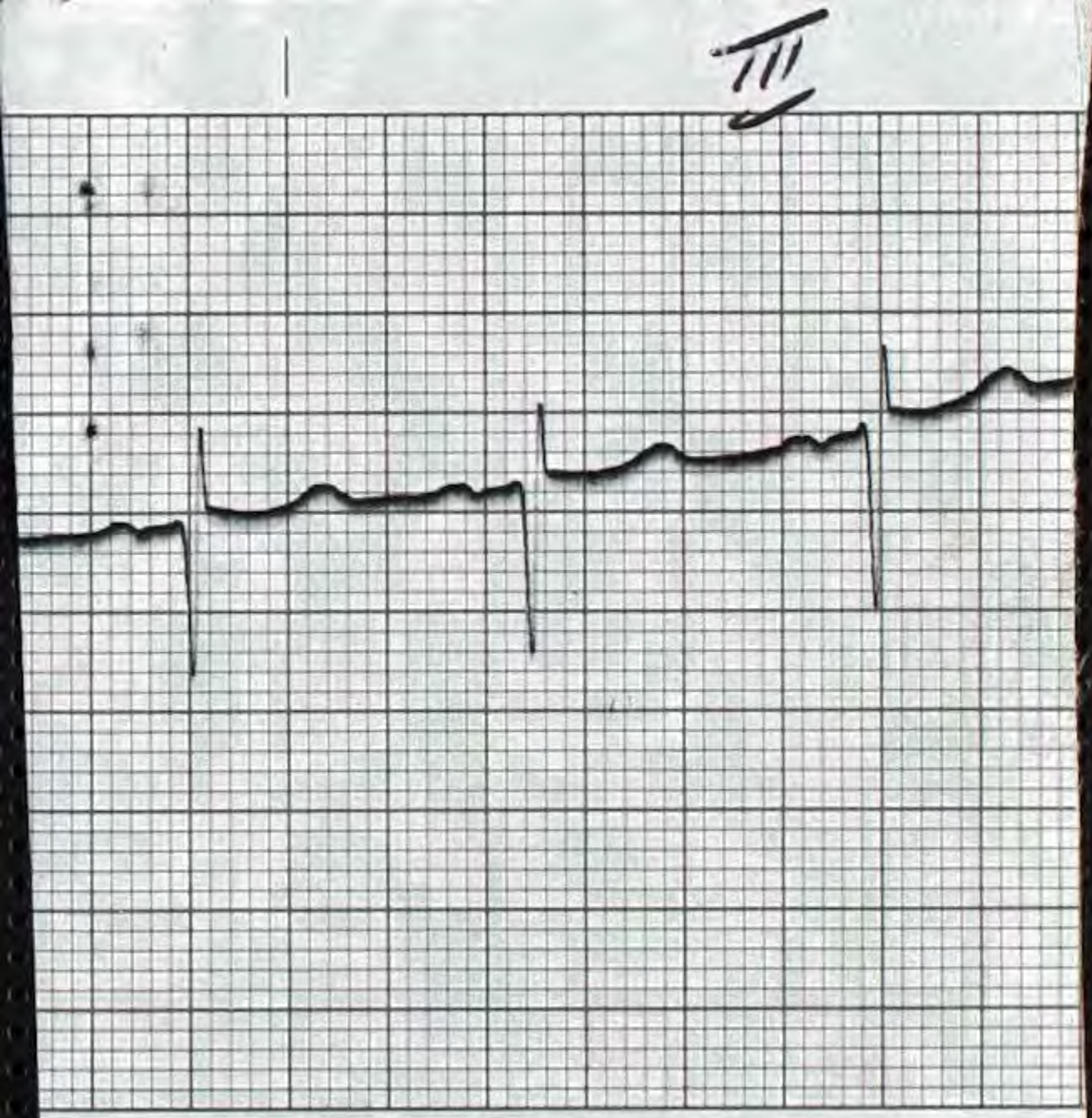
III

AVR

VISO-CARDIETTE *Permapaper*

AVL

AVF

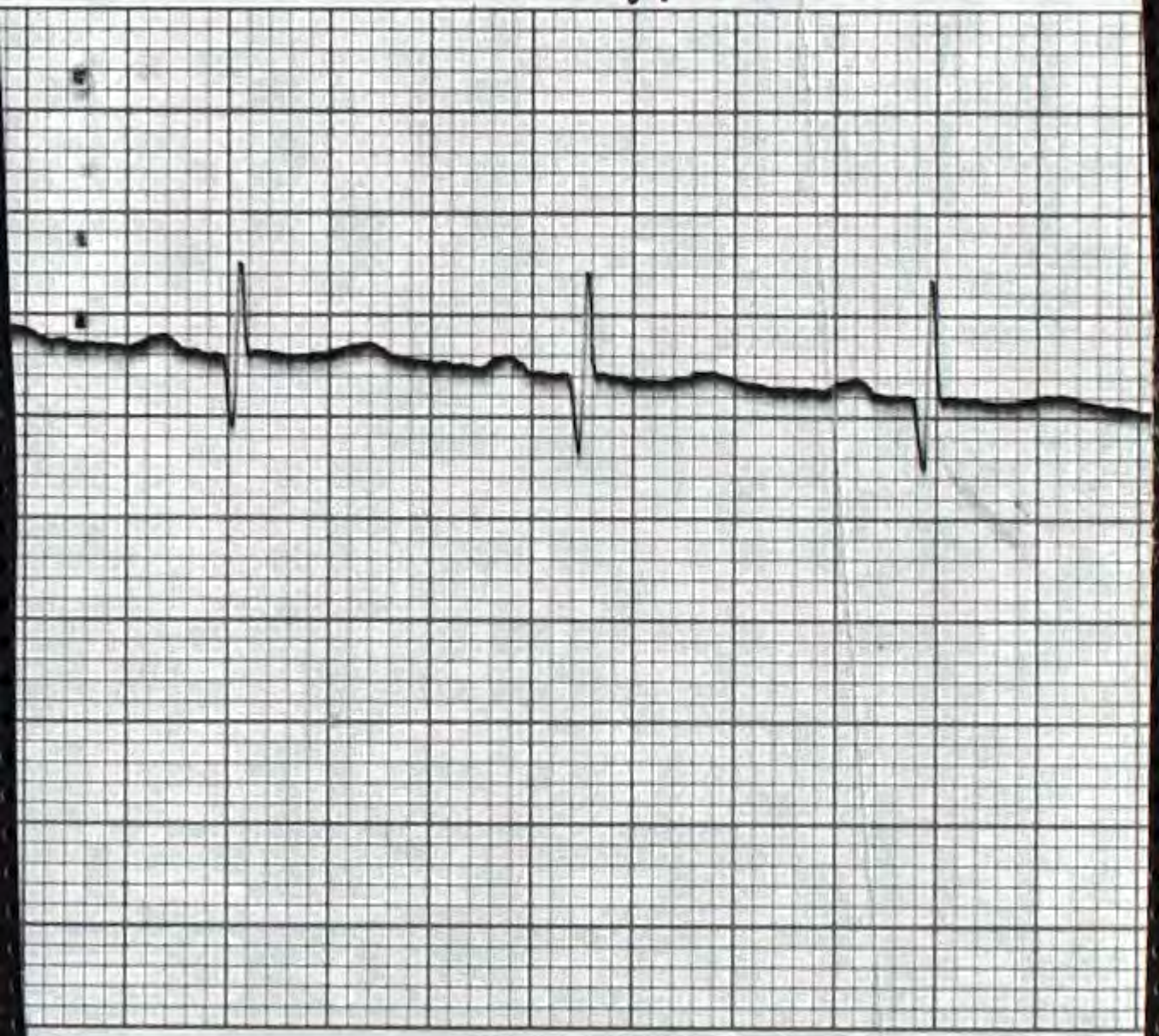

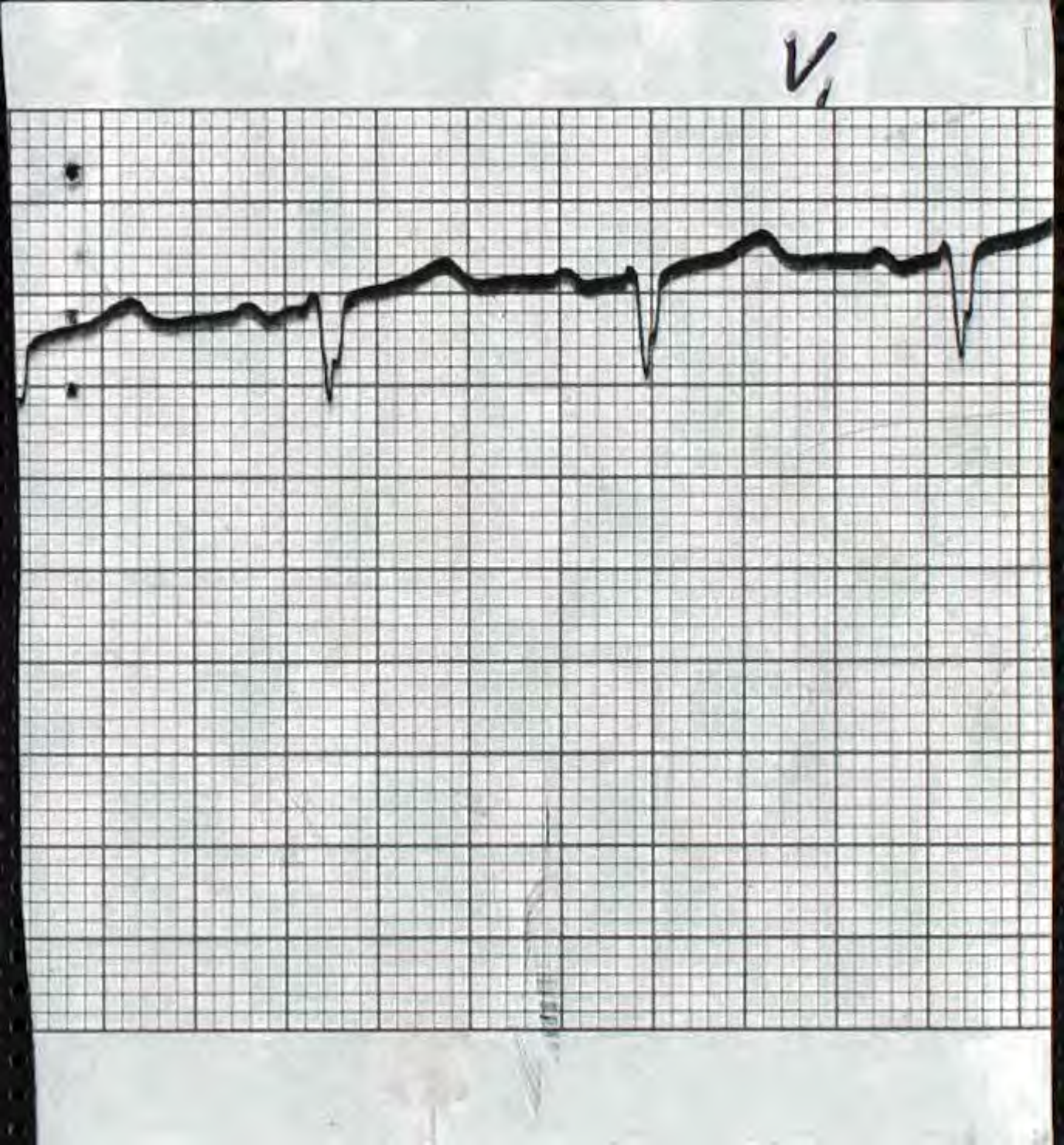
V1

V2

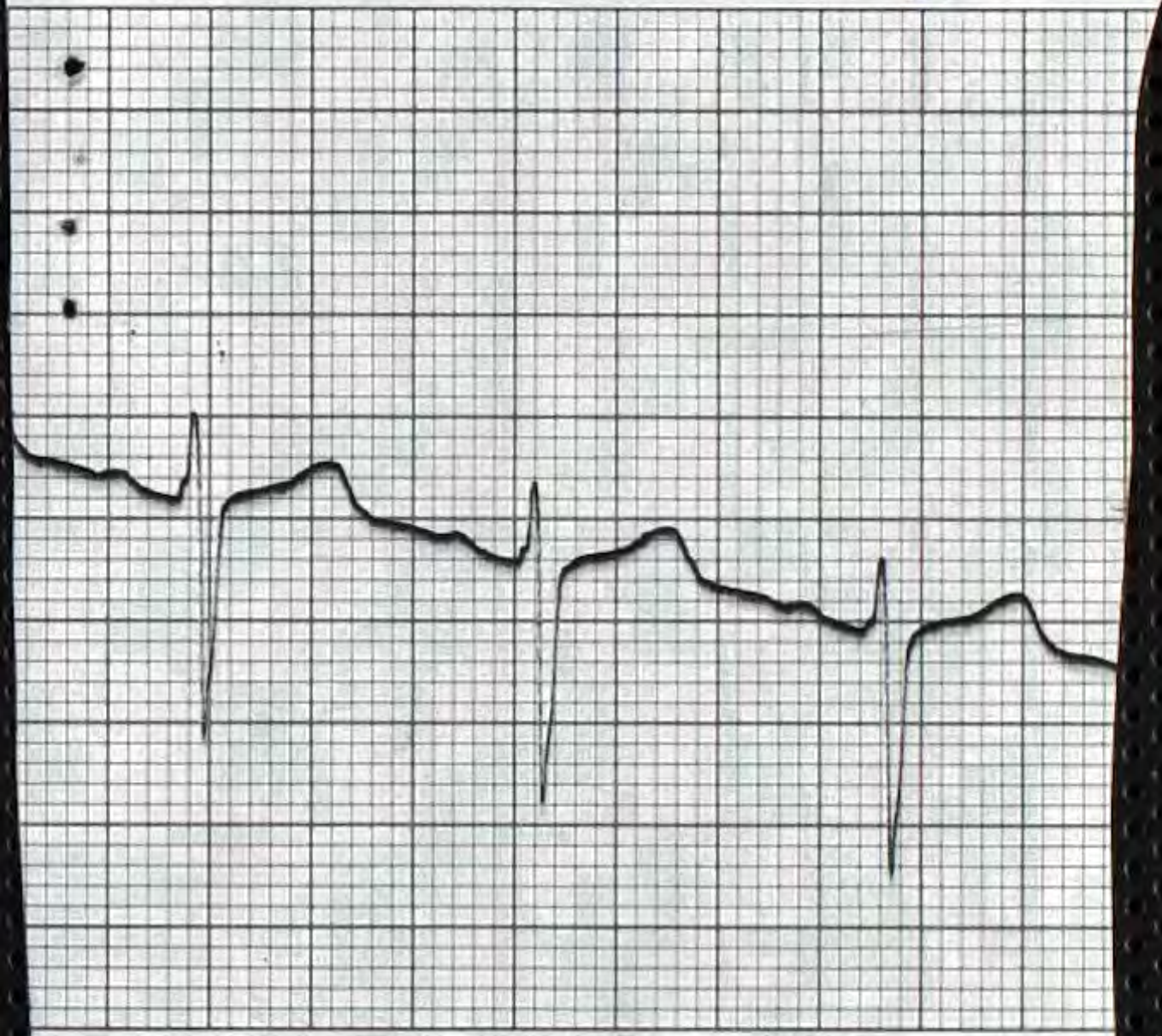


V3

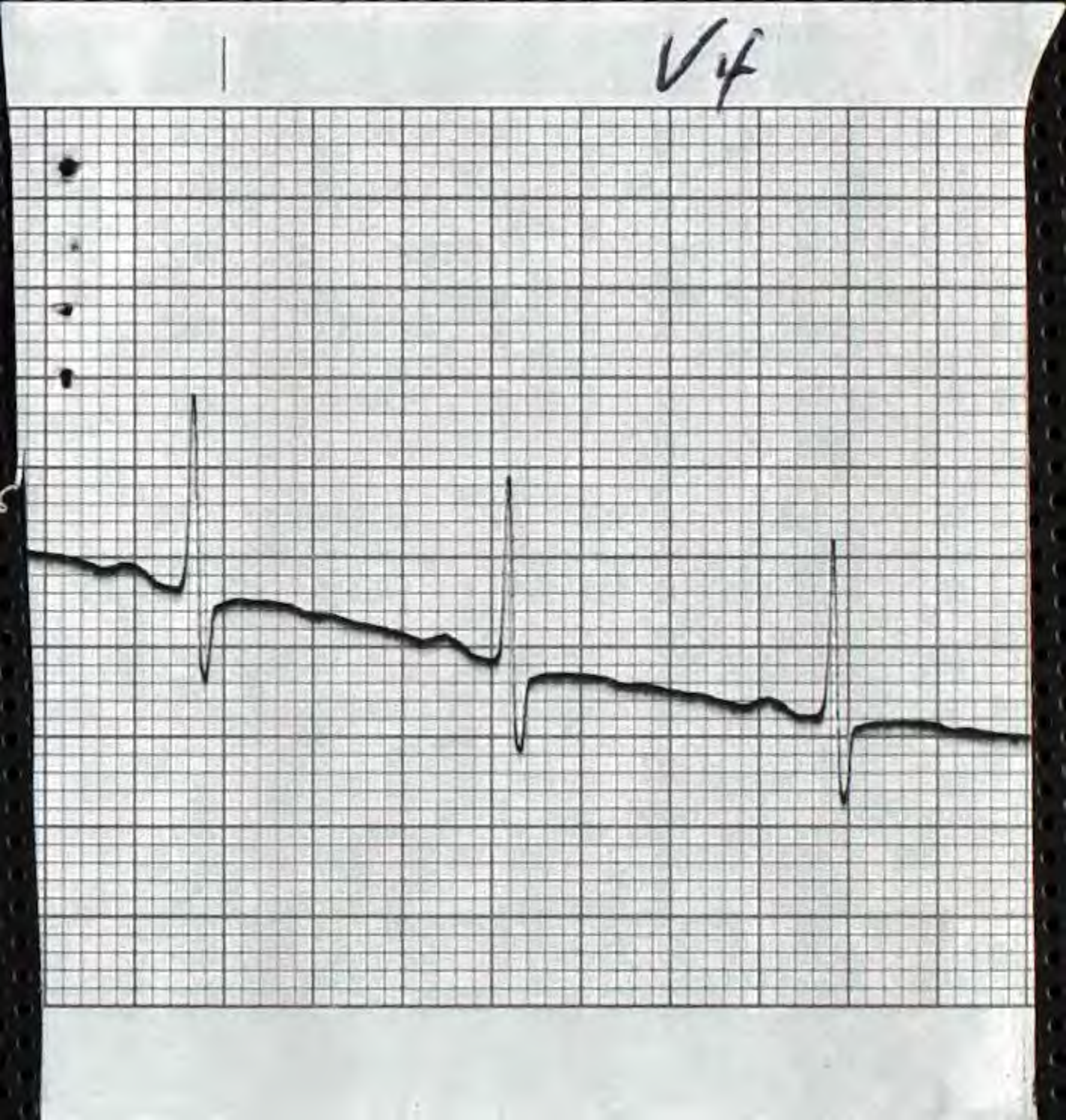
Vf

V5

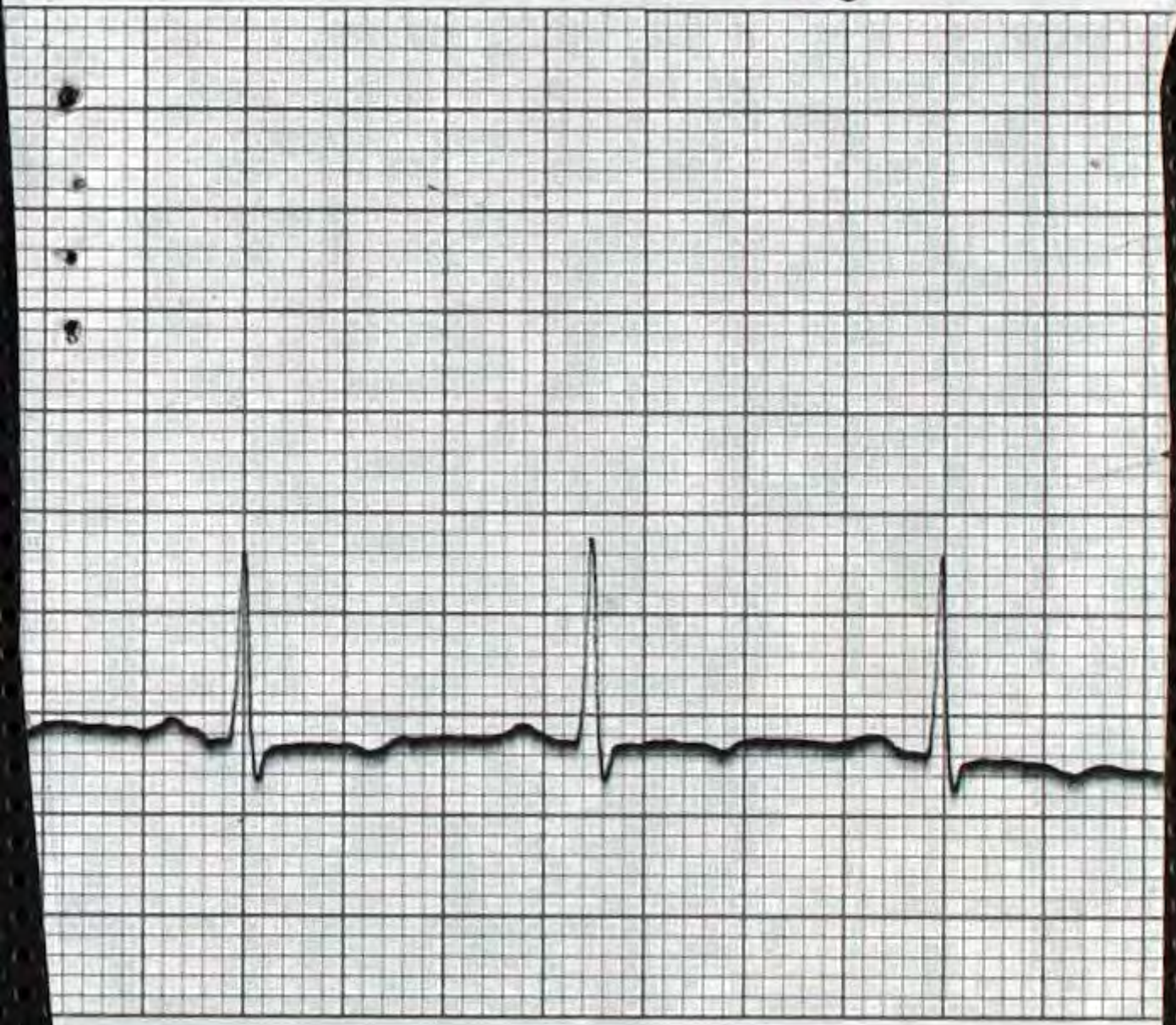

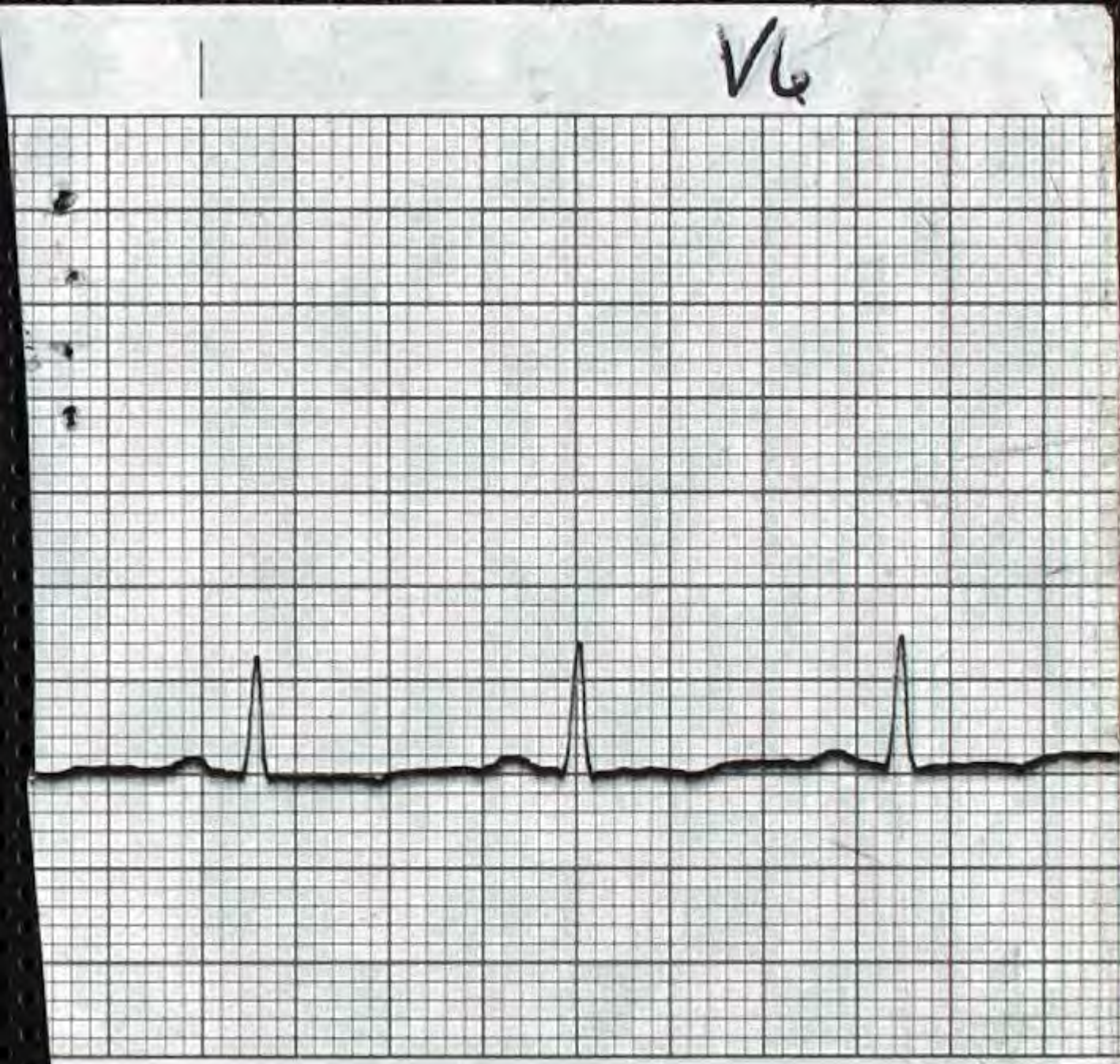
V6

I

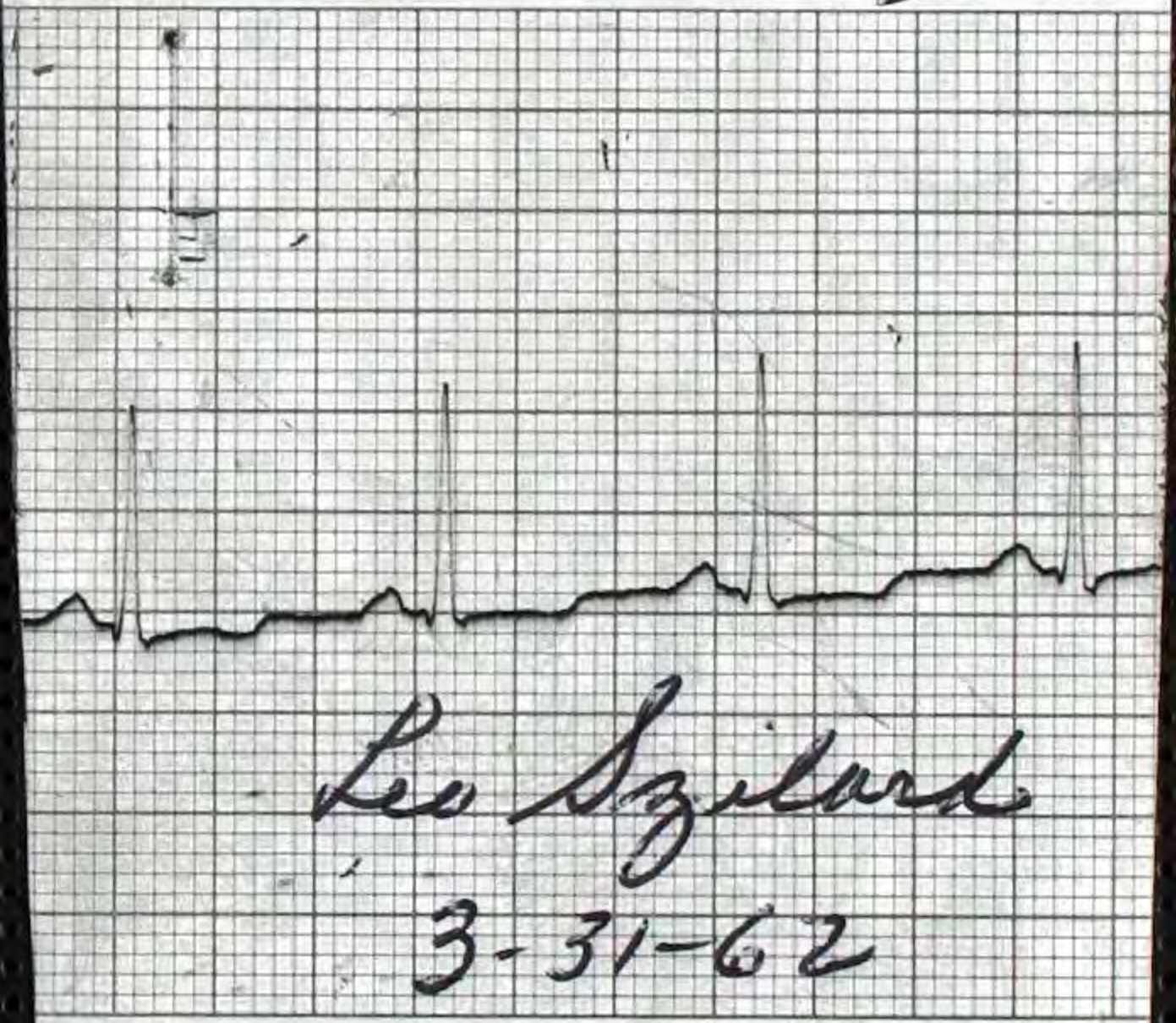

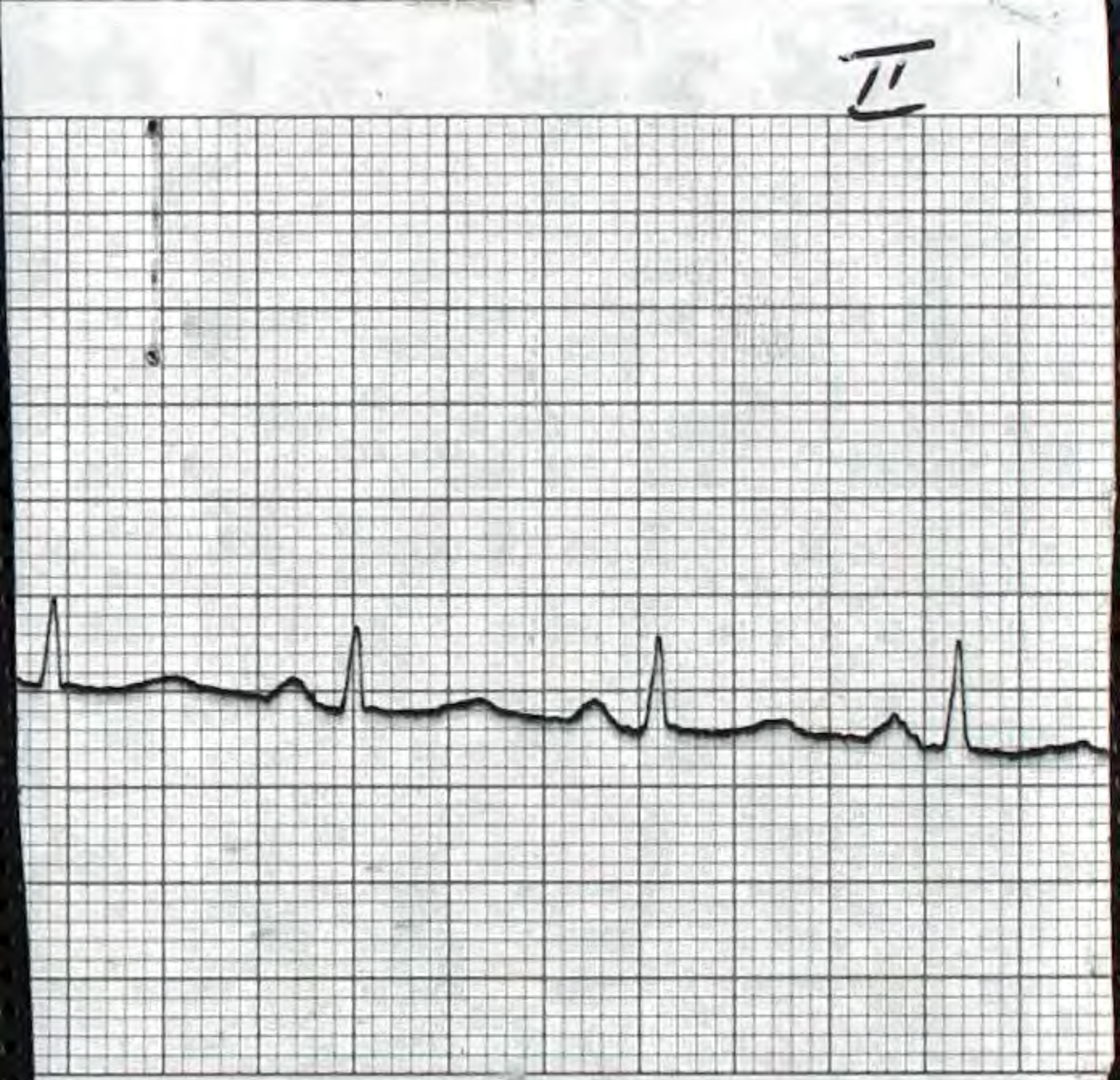
II

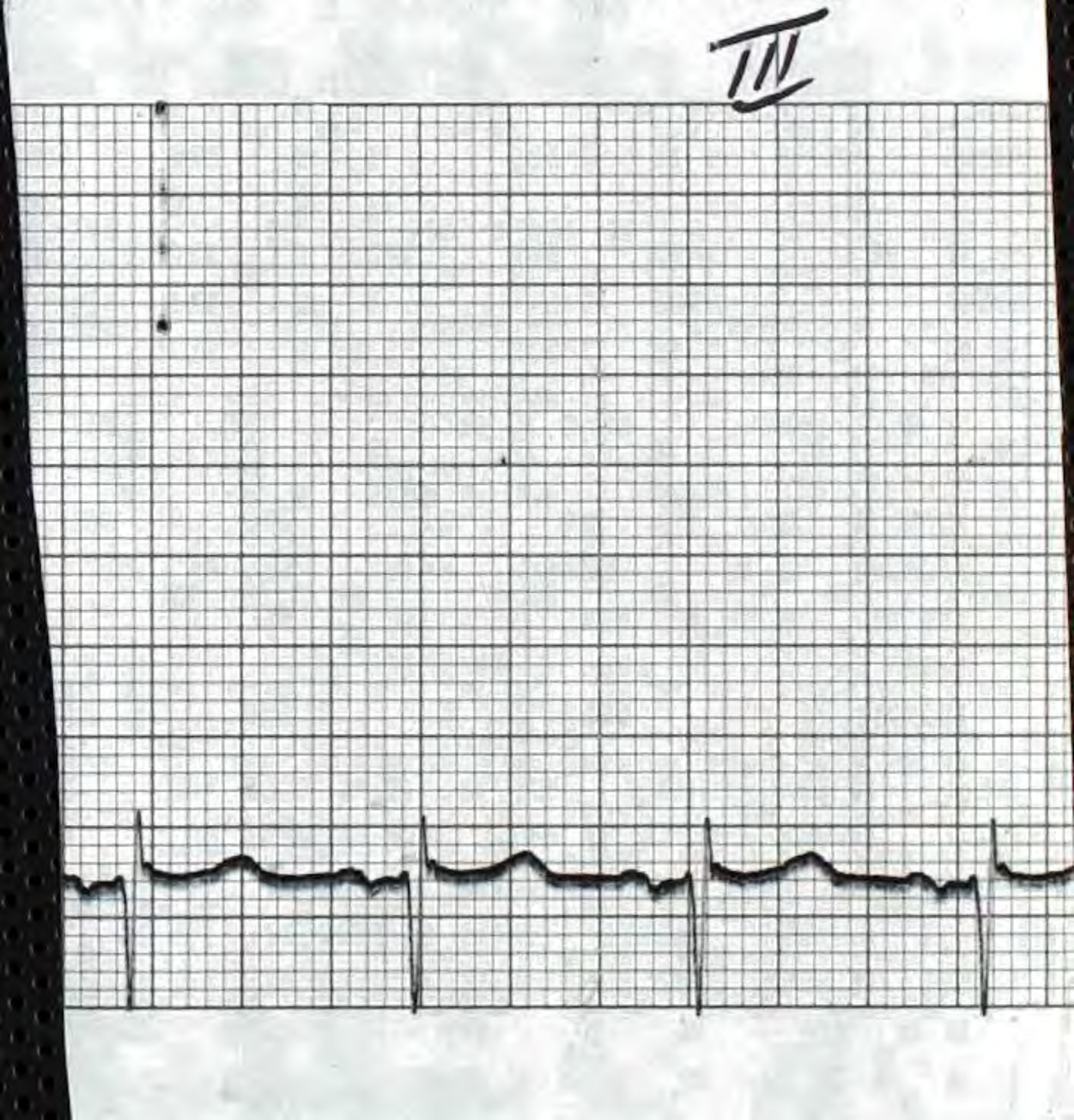
III

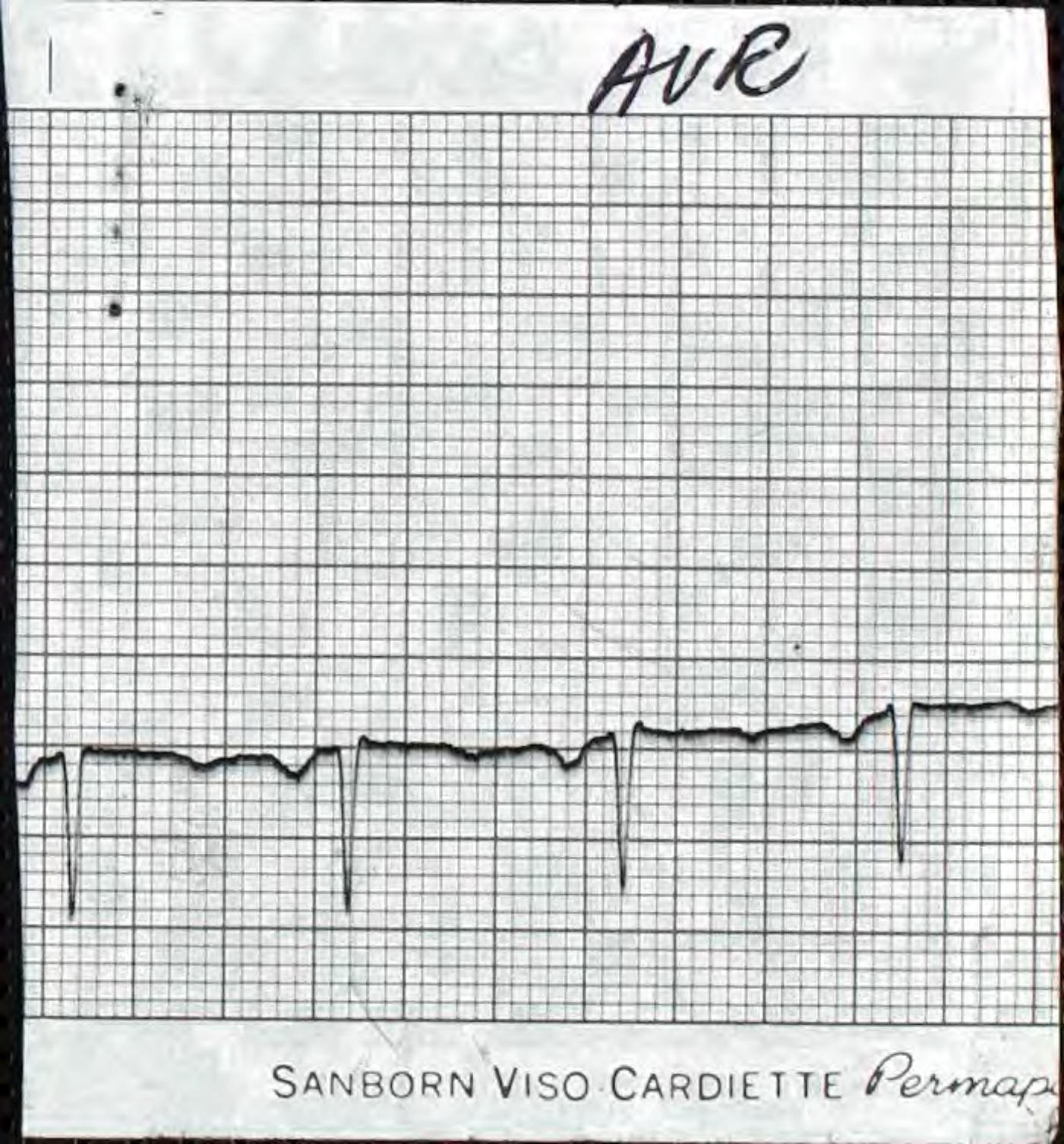
AVR
SANBORN VISO CARDIETTE Permap

AVL

AVF

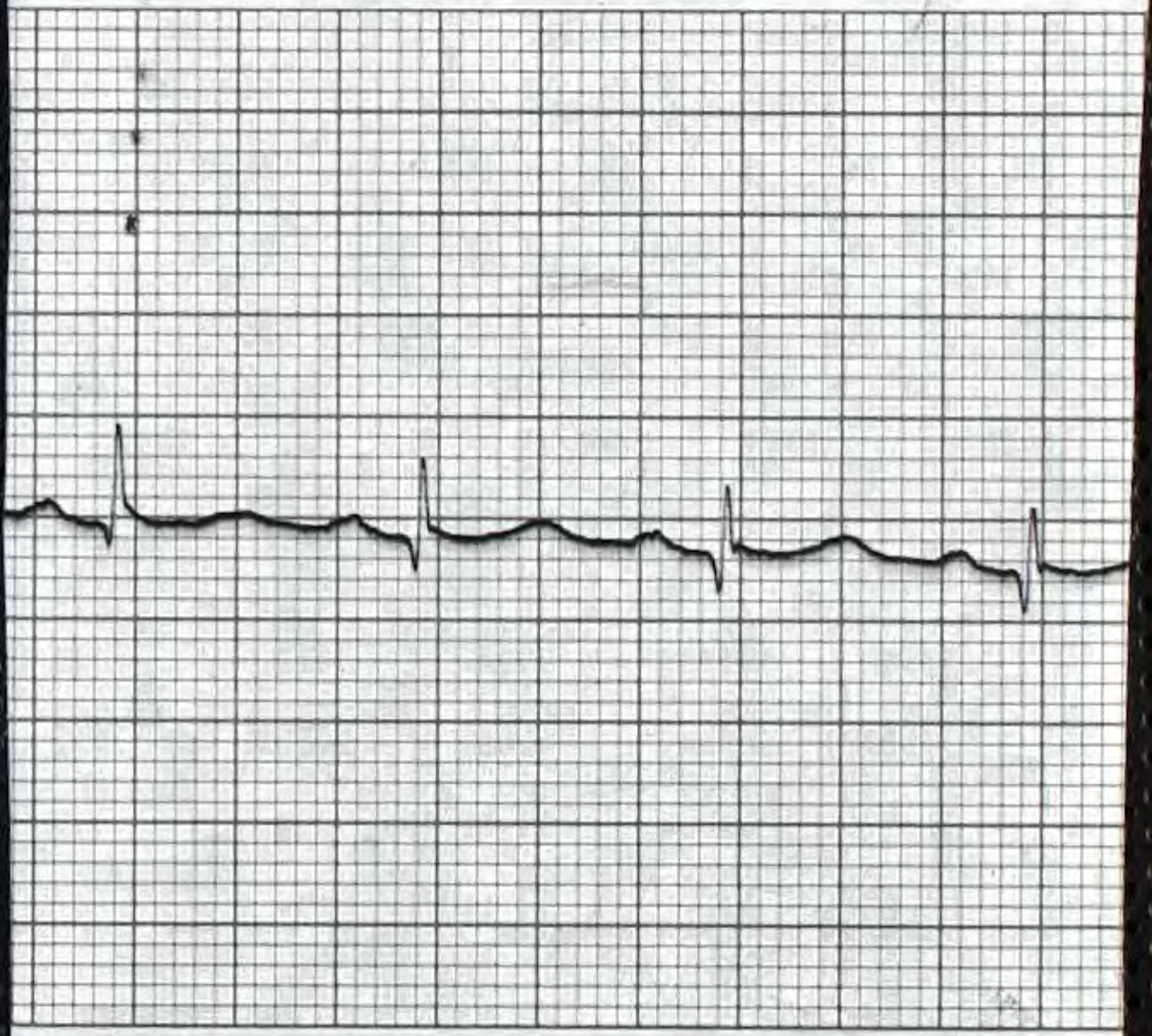

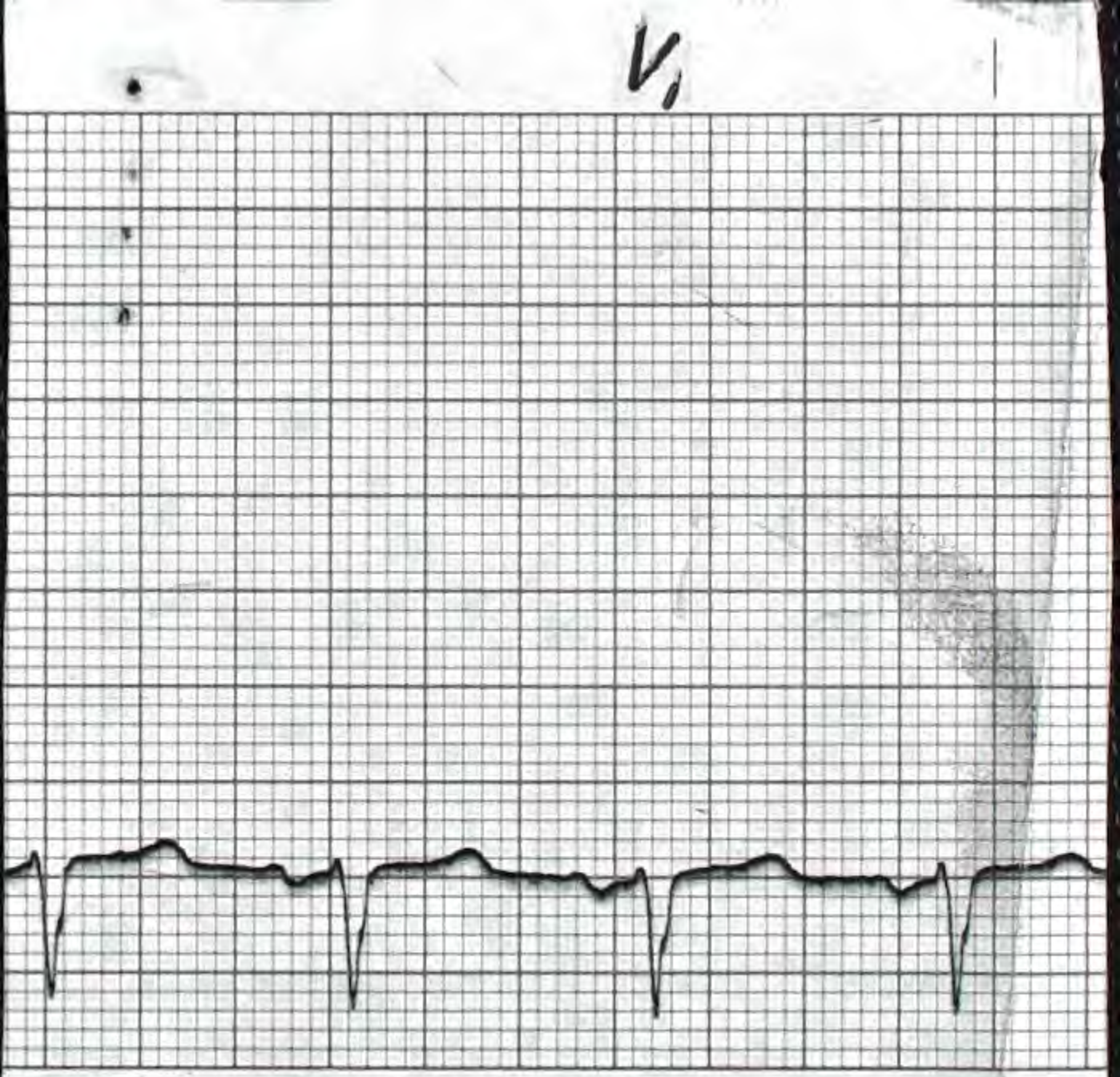

N VISO CARDIETTE *Permapaper*

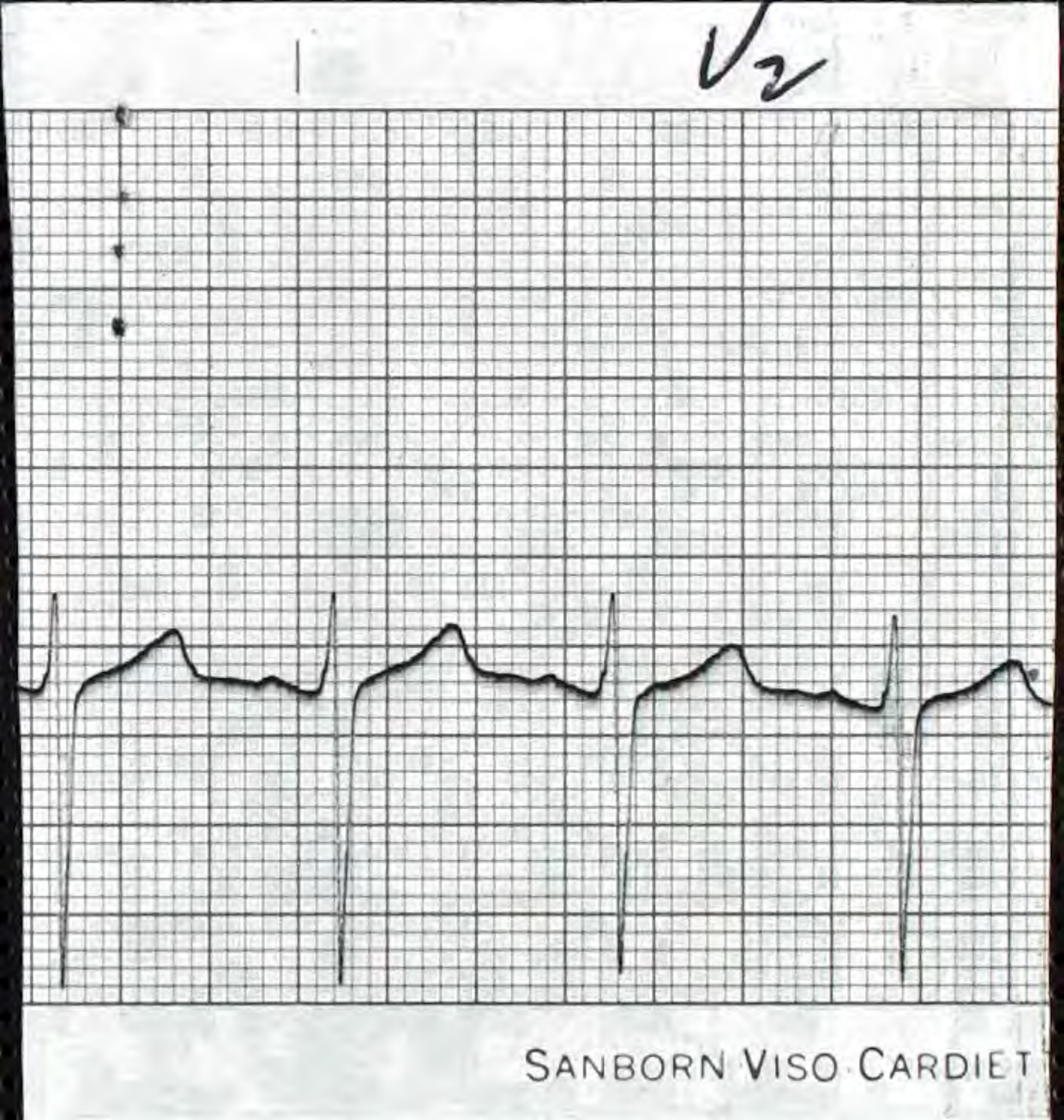
V2
SANBORN VISO CARDIET

V3

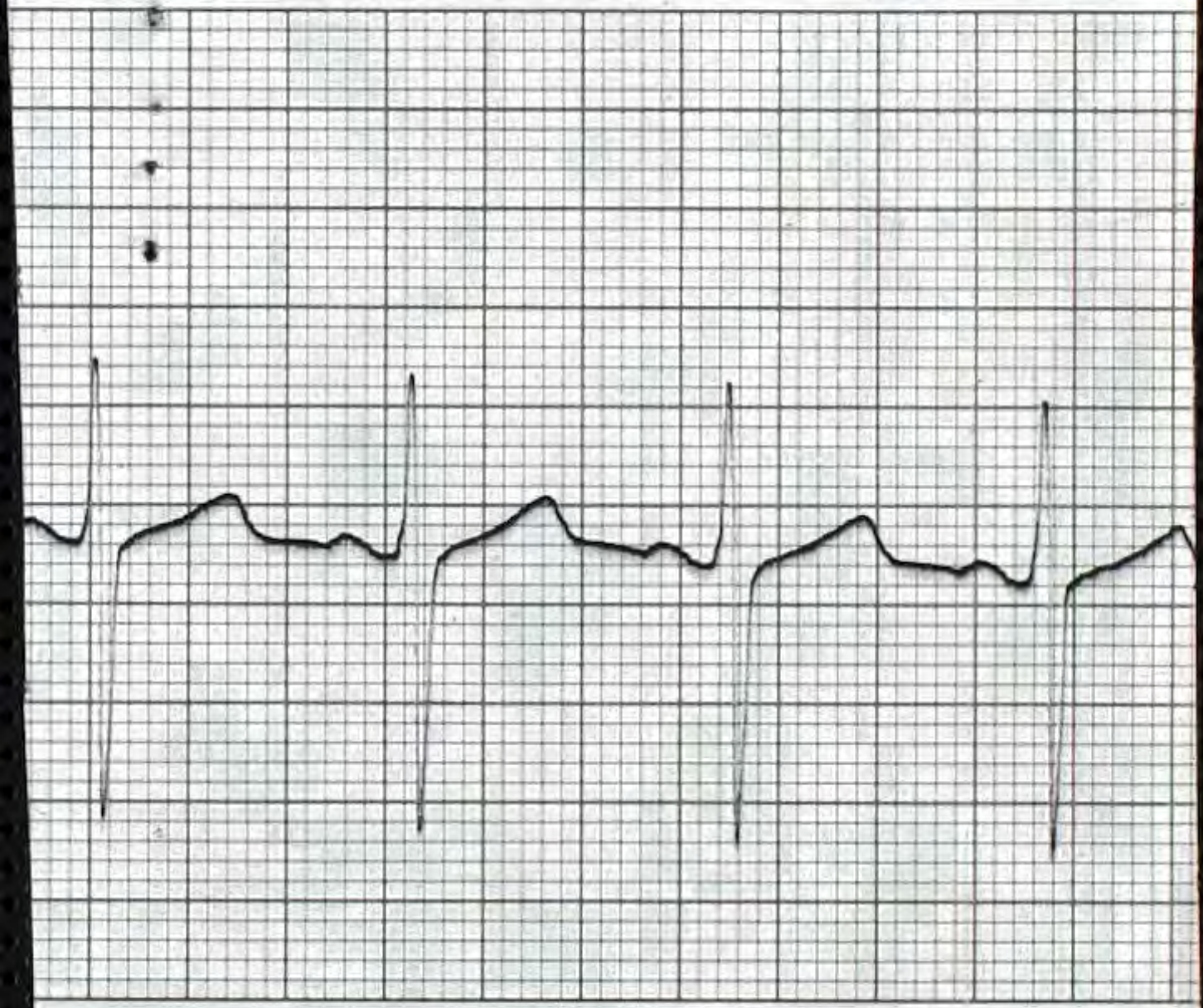

V4

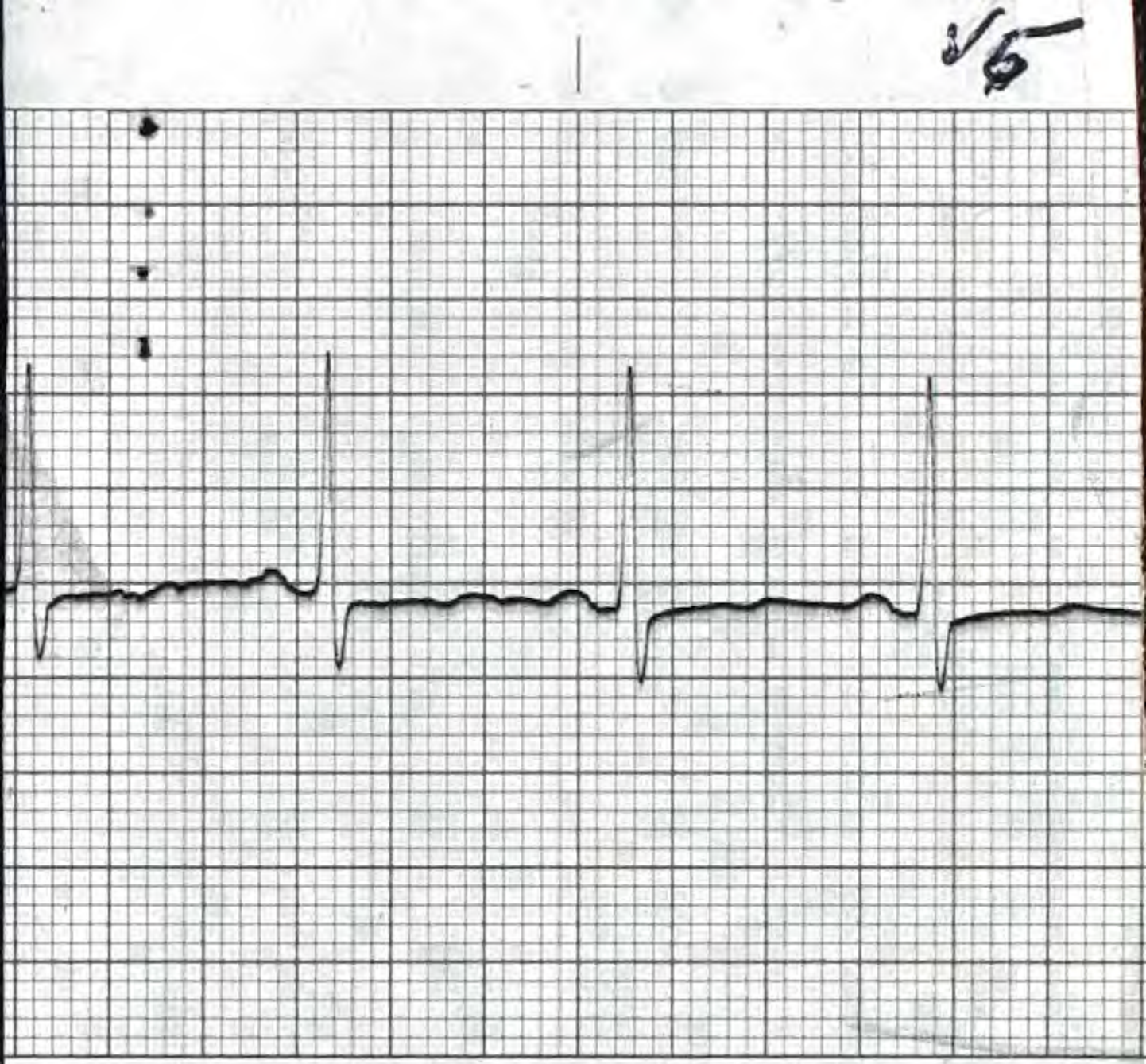

N6

aper

2-8372

TELEPHONE UN 2-2267 REG. No. 2923

RUFUS C. MORROW, M.D.

96 COLCHESTER AVENUE BURLINGTON, VERMONT

NAME _____

ADDRESS _____ DATE _____

℞

Wet wick with 3 or 4 drops of medicine every 4 hours.

Remove wick in 24 hours. Then put 3 or 4 drops of medicine in ear twice daily.

REFILL 0-1-2-3-4 _____ M.D.

Dr. Leo Szilard

6-23-63 Catheterized urine specimen.

No cytologic evidence of a malignant neoplasm is found. PMN's are fairly numerous.

Class I

J.F.Seybolt
Papanicolaou Cytology Lab.

Szilard, Dr. Leo (C62-26839) Dr. Whitmore 12/12/62

Catheterized urine specimen of 12/3/62

No cytologic evidence of a malignant neoplasm is found.

Crystals are numerous.

Class I

N. Lowe

Papanicolaou Cytology Laboratory

SZILARD, DR. LEO (C62-21444) Dr. Whitmore 10-8-62

Catheteterized urine specimen

There are some altered cells in this specimen but they are considered to be of a benign nature.

PMN's are fairly numerous.

Class II

J.F.Seybolt
Papanicolaou Cytology Laboratory

Szilard, Dr. Leo (C62-11785) Dr. Whitmore 6/4/62

Catheterized urine specimen of 5/31/62

No cytologic evidence of a malignant neoplasm is found.

PMN's are fairly numerous.

Class I

N. Lowe
Papanicolaou Cytology Laboratory

Szilard, Leo (C62-5641) Dr. Whitmore 3/15/62

Catheterized urine specimen of 3/13/62

There are some altered cells in this specimen but they are considered to be of a benign nature.

The specimen contains some pmn's and many fungal spores and hyphae.

Class II

N. Lowe
Papanicolaou Cytology Laboratory

JUdson 2-2642

576 FIFTH AVENUE

NEW YORK 36, N. Y. 6/1 19 53

Mr. L. Szillard

TO RUDOLPH LINZ, D. D. S.

FOR PROFESSIONAL SERVICES

Bal. $160.00

THANK YOU.


D/4
B/2



110A–5M-701586(58) 114

THE CITY OF NEW YORK

DEPARTMENT OF HEALTH

OFFICE OF THE COMMISSIONER

For Leo Szilard

Memorial Hospital

East 68th St

My best to both

I your too

Frosa

TO OBTAIN KREBIOZEN

It is necessary to have a physician write to:

Dr. Stevan Durovic
Krebiozen Research Foundation
Banker's Building: Suite 1920
105 West Adams Street
Chicago 4, Illinois

The physician requesting the drug must accompany the request with a case history of the patient.

The Krebiozen Foundation is working in accordance with the rules of the Federal Food and Drug Administration which prohibit it from giving out the names of doctors using the drug. The request must therefore come from a doctor willing to use it.

Dr. Ivy's monograph, OBSERVATIONS ON KREBIOZEN IN THE MANAGEMENT OF CANCER, records Krebiozen as being 68% effective in the alleviation of pain and 50% effective in decreasing tumors.

MEMORIAL CENTER

FOLLOW-UP AND PROGRESS NOTES

NAME
LAST (IN CAPITALS) First (in lower case) Middle

CASE NO.

Stage C total mastectomy — high grade

2 to 3rd year 4/11
3 to 4th year 0
4 to 5 year 1/6
5 to 6 2/3

FORWARD

FOLLOW UP NOTES

5

10185

Some RBC
3-4 WBC

culture 4
12-4-61

---

4 organisms

E. coli
Aerobacter
Proteus
Pseudomonas

over 100,000 pseudomonas
pens. Polymixin We
" COLISTRIN (?) Culture 2
11-22-61

resist. Chloramphenicol
Tetracycline
Furadantin
Kant.

cells

Szilard, Leo Dr
Hotel Du Pont
Du Pont Plaza
Washington 6, Pa

LABORATORY OF CLINICAL PATHOLOGY
OF THE BRYN MAWR HOSPITAL

Diagnosis _____ Age _____ Date _____

Outside: Priv. ☑ Semi-Priv. ☐ Clinic ☐ Charge _____

Physician Bourie Culture T

Extension 11-20-61

MICROBIAL SENSITIVITY TO THERAPEUTIC AGENTS
Material and Source Urine

Organism ① Coliform ② Proteus

☐ ROUTINE ☐ SIMULTANEOUS ☐ SPECIAL ☐ ZONAL

	1 Sensitive	2	1 Resistant	2
Penicillin			✓	✓
Streptomycin			✓	✓
Chlortetracycline (Aureomycin)			✓	✓
Oxytetracycline (Terramycin)			✓	✓
Tetracycline (Achromycin)			✓	✓
Erythromycin (Ilotycin)			✓	✓
Chloramphenicol (Chloromycetin)	✓			✓
Furadantin			✓	✓
Polymixin B				

		1 Sensitive	2	1 Resistant	2
Zonal Penicillin	Low				
	Medium				
	High				
Magnamycin					
Neomycin					
Bacitracin					
Gantrisin		✓			✓
Triple Sulfa					

Date Reported: 11-22-61

BACTERIOLOGY 2 Hell.

Date of Collection 11-21-61 Time of Collection 11-20

F 5088

SZILARD, LEO (DR.)
HOTEL DU PONT
DU PONT PLAZA
WASHINGTON 6, D.C.

LABORATORY OF CLINICAL PATHOLOGY OF THE BRYN MAWR HOSPITAL

Diagnosis _____ Age _____ Date 11/20/61

Outside: Priv. ☑ Semi-Priv. ☐ Clinic ☐ Charge _____

Physician Dr. Bowie

Source: Extension

Sputum:
- Quantity, 24 hours
- Appearance
- TB direct smear
- TB concentrated smear
- TB culture

Spinal fluid:
- Gross Appearance
- Wbc ____ /mm³ Rbc ____ /mm³
- Polys. ____%; Lymphos ____%; Monos ____%

MATERIAL:
- ☐ Blood
- ☐ Sputum
- ☑ Urine
- ☐ Feces
- ☐ Spinal Fluid
- ☐ Gastric content
- ☐ Exudate
- ☐ Pus
- ☐ Secretion
- ☐ Drainage
- ☐ Pleuritic fluid
- ☐ Ascitic fluid

SUSPECTED INFECTIOUS AGENT:
- ☐ Anaerobic organism
- ☐ Gonococcus
- ☐ Pertussis
- ☐ Streptococcus
- ☐ T.B.
- ☐ Brucella
- ☐ Fungus
- ☐ Diptheria
- ☐ Fusospirochete (Vincent's)
- ☐ Salmonella Shigella
- ☐ Pneumococcus
- ☐ Ova & Parasites

EXAMINATION REQUESTED
- ☑ Culture, routine
- ☐ Smear
- ☐ Culture T.B.
- ☐ Smear—direct—T.B.
- ☐ Smear—concentrated—T.B.
- ☐ Vaccine
- ☐ Dust Extract
- ☐ Dark Field
- ☐ Cell Count
- ☐
- ☐
- ☐
- ☐

Smear:

Culture: loaded with Coliform; Proteus also present.
P.S. "Coliforms" were non-hemolytic on Bovine
Please do sensitivities

Date Reported: 11-21-61

BACTERIOLOGY 1

Date of Collection 11-20 Time of Collection _____

F 5087

FROM

_____

_____

_____

J. R. PALKIN, D. D. S.
G. A. AUDETTE, D. D. S.
COLUMBIA MEDICAL BUILDING
1835 EYE STREET, N. W.
WASHINGTON 6, D. C.

Dr Leo Szilard
Du Pont Plaza NW
Room 745 DC

J. R. PALKIN, D. D. S.
G. A. AUDETTE, D. D. S.
COLUMBIA MEDICAL BUILDING
1835 EYE STREET, N. W.
WASHINGTON 6, D. C.

NATIONAL 8-2071
REPUBLIC 7-4600

Oct 1, 1961
DATE

FOR PROFESSIONAL SERVICES: $ 10.00

USE THIS ENVELOPE FOR YOUR REMITTANCE

GEORGE N. WISE, M. D.
30 WEST 59TH STREET
NEW YORK 19, N.Y.

Dr 3:1259
Gaskins

Take 2 at
beginning of diplopia

Diamox.

CHAUNCY
HARRIS